

Case Report: Double Gingival Metastasis of Hepatocellular Carcinoma

Reda Hamdi, Laura Tissot, Christophe Guichard, Patrick Manipoud

ENT department of the metropole savoie regional hospital Hôpital de Chambéry, Place Lucien Biset, Fbg Maché, 73000 Chambéry, France.

Article Info

Received: March 29, 2023

Accepted: April 03, 2023

Published: April 10, 2023

***Corresponding author:** Reda Hamdi, ENT department of the metropole savoie regional hospital Hôpital de Chambéry, Place Lucien Biset, Fbg Maché, 73000 Chambéry, France.

Citation: Hamdi H, Tissot H, Guichard C, Manipoud P. (2023) "Case Report: Double Gingival Metastasis of Hepatocellular Carcinoma", *Clinical Oncology Case Reports and Research*, 1(1); DOI: <http://doi.org/04.2023/1.1001>.

Copyright: © 2023 Reda Hamdi. This is an open access article distributed under the Creative Commons Attribution License, which permits unrestricted use, distribution, and reproduction in any medium, provided the original work is properly cited.

Abstract:

This article reports a case of gingival metastasis of hepatocellular carcinoma (HCC) in a 70-year-old Asian patient. The patient presented with a painful, rapidly growing gingival mass that was ultimately diagnosed as a metastasis of HCC. This case highlights the importance of considering metastatic disease as a differential diagnosis when evaluating oral lesions, particularly in patients with a history of cancer. The article also discusses the possible mechanisms and routes of metastasis of HCC to the gingiva, as well as the treatment options for this rare manifestation of HCC.

Key words: case report; hepatocellular carcinoma; gingival; metastasis

Introduction

Hepatocellular carcinoma (HCC) is France's second leading cause of digestive cancer. It represents 0.5 to 2% of all cancers, with approximately 6,000 new cases annually in France. HCC occurs in cirrhotic livers in more than 85% of cases, mainly of alcoholic or viral origin [1]. Most patients are male (male to female ratio, 46:4) and over 50 years old in 90% of cases [2]. Extrahepatic metastases occur in 25 to 37% of cases [3;4]. cases and preferentially involve the lungs, regional lymph nodes, locomotor adrenal glands, and rarely the oral region [5;6].

Oral metastases of HCC are present in 30% of cases before discovering primary cancer [7]. The mandibular bone is most often affected [8]. Gingival metastases are rare [6, 9]. When present, it is often associated with other localizations, particularly pulmonary [10].

Narrative

The case presented is a new case of gingival metastasis of a mandibular HCC occurring in a 70-year-old woman from China who speaks only Chinese, She was hospitalized in the department of gastroenterology and digestive oncology and addictology of the metropole Savoie hospital of Chambéry for chemotherapy for hepatocellular carcinoma in evolutive pursuits on autoimmune cirrhosis with iterative punctures of the ascites liquid within the framework of peritoneal carcinoids. It should be remembered that the patient was treated for a recurrent uni-focal hepatocellular carcinoma by segmentectomy of segment VII at the University Hospital of Grenoble Alps whose anatomopathological results had found a low differentiated hepatocellular carcinoma of EDMONSON grade III.

The treatment was completed by chemotherapy at the hospital of Chambéry in August 2021, following an evolutive pursuit, and during its follow-up, the patient was very asthenic very painful at the oral level, and presented a mass at the level of the gingival lower labial level, in front of the incisors, rounded and pediculated, well limited, purplish red, bleeding on contact, slightly overflowing extra buccal, very painful, preventing feeding, suggesting a botriomycoma of the gum (figure 1)

The rest of the examination of the oral cavity shows a rather precarious oral and dental condition, the oral mucosa, jugal, and tongue were without particularity, tonsils, and pharynx also.

The rest of the ENT examination, especially rhinological and otological

The nasofibroscopy was also normal.

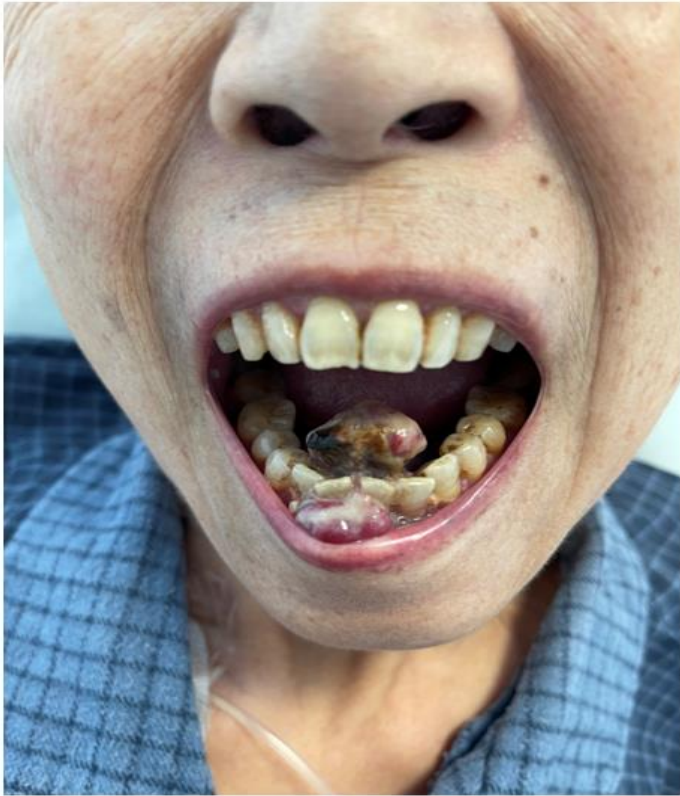

Figure 1: Image showing the gingival metastatic tumor. A reddish and friable gingival mass, originating on both sides of the lower gingiva opposite the insertion of the incisors

Patient Perspective

The patient underwent a biopsy, under local anesthesia, during the same consultation time. While waiting for the results, the patient continued her palliative treatment with chemotherapy. After one week, the results came back in favor of a gingival metastasis of her HCC. Histological examination revealed a neoplasm covered with squamous epithelium interspersed with cells developed in an invasive trabecular pattern surrounded by a sinusoidal network. Broadly resembling hepatocytes, the tumor cells with abundant cytoplasm showed moderate nuclear atypia with few discernible nuclei (Fig. 2). This microscopic appearance was consistent with the diagnosis of HCC. Immunohistochemistry (IHC) supplements showed that the tissue had strong positive reactions to antibodies against hepatocytes, CAM5, and CD10 and low affinity for antibodies against glypican-3, arginase -1, thyroid transcription factor-1, and cytokeratin-7. Finally, the gingival mass was definitively diagnosed as a metastasis of HCC.

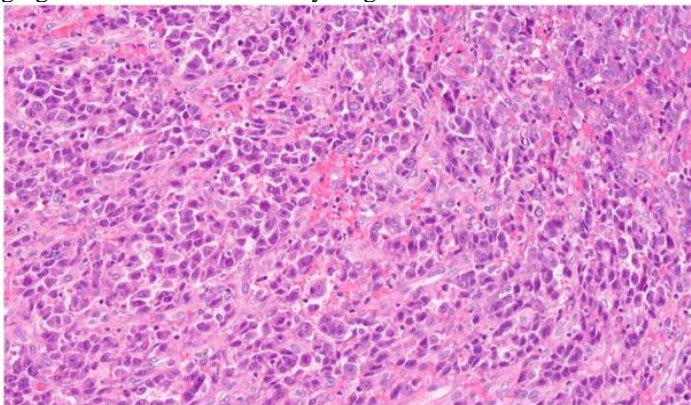


Figure 2: histopathological section. Hematoxylin and eosin stain showing oral squamous mucosa with submucosal proliferation of malignant epithelioid cells arranged in a trabecular architecture. The tumor cells are similar to hepatocytes with moderate nuclear atypia and abundant cytoplasm.

Discussion

According to a large-scale global cancer survey [11], hepatocellular carcinoma (HCC) ranks sixth in global cancer incidence and fourth in cancer mortality. Despite significant reductions in mortality in East Asian countries such as China, South Korea, and Japan, HCC remains the third most common and deadliest cancer. More than 50% of HCC patients have extrahepatic metastases, most commonly involving the lungs, bones, brain, and abdominal lymph nodes [12]. HCC metastases to the gum are considered extremely rare. However, the rarity of gingival metastases may be overestimated; some cases published in English [6, 13,14] or non-English literature [7, 15] journals have not been included in the major databases of the literature. Some cases may not have been reported at all because of potential misdiagnosis. Not all cases are reported because some may be misdiagnosed. Misdiagnosis often occurs when cases have only gingival lesions [7, 14, 16, 17, 18, 19]. There are cases where it is mistaken for gingival benign disease [3, 20], which leads to even more misdiagnosis, especially if there is no biopsy or pathological examination.

Gingival metastasis can originate from a variety of primary sites, including lung, breast, kidney, bone, colon, adrenal gland, and liver [21]. The possible pathophysiological mechanism of HCC metastasis to the gingiva remains to be elucidated. Invasion of branches of the hepatic artery or portal vein is the preferred mode of oral metastasis [22-23], although metastatic lung tumors are absent in some cases [11, 14,19,24-25, 26-27, 28, 29, 30, 31, 32]. In these cases, the valveless vertebral venous plexus (Batson plexus) has been proposed as a mechanism to bypass filtration of the pulmonary, inferior vena cava and portal circulation [33,34]. This pathway may be the most likely to lead to HCC metastasis to the gingiva without pulmonary metastasis. In addition to the Batson plexus, other possible pathways for gingival metastasis include the arterial, venous, and lymphatic circulation [35]. Given that cirrhosis occurs in more than 50% of HCC patients with metastatic gingival tumors, we cautiously elevate the hypothesis that hemodynamic alteration due to esophageal

varices may be one of the pathways for oral metastasis, especially in patients with HCC on cirrhotic liver with incomplete compensation.

At least 30 cases of gingival HCC metastasis have been collected from existing literature resources. Analysis of these cases can help us better understand the clinical and pathologic features of gingival HCC metastases. First, our current analysis suggests that there is a significant sex preference in the occurrence of gingival HCC metastasis. The male- to-female ratio is greater than 6:1 (26:5), far exceeding the overall male-to-female ratio of approximately 3:1 in liver cancer incidence [11]. These inconsistencies raise the question of whether relatively poor general health habits or oral health behaviors (such as smoking and alcohol consumption) in men, as revealed in one study [36], promote gingival HCC metastases. The pathogenesis of this particular metastasis is thought to be related to oral inflammation, such as gingivitis, which eventually attracts cancer cells to migrate and adhere to the gum [23]. Chronic inflammation is involved in various stages of tumorigenesis, including cell



transformation, survival, proliferation, invasion, angiogenesis and metastasis [37,38]. The rich capillary network of chronically inflamed gingiva and the presence of certain inflammatory molecules may promote the progression of metastatic cells [23]. Further research on this possible mechanism remains to be done. Additionally, an analysis of survival data revealed that patients who initially displayed a gingival mass as a sign of HCC had a very low survival rate. This inaccurate assessment of survival may have been caused by concurrent numerous extra hepatic metastases.

Nevertheless, there have only been three reports of distant metastases outside the gingiva among HCC cases with gingival lesions as the primary symptom [16, 19, 39]. In this scenario, the survival may be made worse by the delay in diagnosis and treatment, which is partially due to the lack of subacute liver cancer symptoms. This highlights the significance of early diagnosis and treatment of any potential gingival metastases from HCC or other distant tumors. Even if a tumor looks similar, a timely biopsy is required.

Moreover, the HCC is more likely to spread to the upper gingiva than the lower one. We discover several structural factors for this diffusion preference by studying the anatomy. The anatomical features of the gingival arteries that irrigate them may make a difference. The upper respiratory tract's two main blood vessels—the sub-orbital and dental upper arteries—take in blood. The two arteries have larger diameters and larger volume of blood as they are directly extensions of their maxillary artery [40].

Meanwhile, the lower gingiva only accepts blood through a smaller artery called the inferior dental artery, which is a thinner branch of the maxillary artery. The increased blood flow can increase the risk of implantation by circulating tumor cells to the upper gingiva.

Early diagnosis of a gingival mass metastasized from an underlying primary cancer was critical to patient prognosis. However, misdiagnosis or missed diagnosis can result from several factors. First, the low incidence rate and indistinct manifestations (bleeding, swelling, ulceration, etc.) have posed new challenges for physicians to recognize this rare disease. Second, the misleading characteristics of gingival lesions, such as mimicking pyogenic granuloma or botriomycoma [3, 20], would make physicians forget about the need for a biopsy. However, the rapid growth characteristic of a gingival mass may put physicians on alert for a malignancy. As indicated in the present case, the gingival lesion was initially diagnosed as a primary gingival tumor (botriomycoma) until the biopsy and pathological test were completed; then, an HCC metastasis was finally identified [41].

treatments for primary hepatocellular carcinoma involved hepatectomy, chemotherapy, transarterial chemoembolization (TACE), transcatheter arterial embolization (TAE), novel targeted cancer therapy (sorafenib), and combination therapy. Primary treatments for gingival lesions included resection, chemotherapy, radiotherapy, and TAE. The effectiveness of treatment for survival remains to be confirmed on the basis of large sample randomized controlled studies. As an integral part of evidence-based medicine, case reports and literature reviews have profoundly influenced the medical literature, and they continue to advance our knowledge of disease and help generate hypotheses for conducting clinical studies and basic research.

Conclusion

The diagnosis of a metastatic gingival lesion in patients is challenging because to the rarity of this kind of primary liver

cancer. Even if no clear clinical presentation is present, a biopsy is necessary to prevent a potential incorrect diagnosis. A timely diagnosis and treatment of early-stage liver cancer or a metastatic gingival lesion may increase the chance of survival.

Consent:

Informed consent was obtained from all participants included in the study.

Conflict of Interest:

The authors declared no conflict of interest.

References

- Blanc JF, Debaillon-Vesque A, Roth G, Barbare JC, Baumann AS, Boige V, Boudjema K, Bouattour M, Crehange G, Dauvois B, Decaens T, Dewaele F, Farges O, Guiu B, Hollebecque A, Merle P, Selves J, Aparicio T, Ruiz I, Bouché O; Thésaurus National de Cancérologie Digestive (TNCD); (SNFGE, FFCF, GERCOR, UNICANCER, SFCD, SFED, SFRO, AFEF, SIAD, SFR/FRI). Clin Res Hepatol Gastroenterol. 2021 Mar;45(2):101590. doi: 10.1016/j.clinre.2020.101590. Epub 2021 Mar 26. PMID: 33780876.
- Chen, L. X., Dai, X. Y., Chen, X. X., Zhou, D. H., and Chen, Y. (1998). Effect of Gujin moji tablet on leukocyte of tumor bearing mice after chemotherapy. *Cancer Res. Prev. Treat.* 25, 245–246.
- J. Ramón Ramirez, J. Seoane, J. Montero, G.C. Esparza Gómez, R. Cerero Isolated gingival metastasis from hepatocellular carcinoma mimicking a pyogenic granuloma *J Clin Periodontol*, 30 (10) (2003), pp. 926-929
- Fujiwara Y, Shiba H, Furukawa K, Iida T, Haruki K, Gocho T, Wakiyama S, Hirohara S, Ishida Y, Misawa T, Ohashi T, Yanaga K: Glasgow prognostic score is related to blood transfusion requirements and post-operative complications in hepatic resection for hepatocellular carcinoma. *Anticancer Res* 30: 5129-5136, 2010.
- Katyal S, Oliver JH 3rd, Peterson MS, Ferris JV, Carr BS, Baron RL. Extrahepatic metastases of hepatocellular carcinoma. *Radiology*. 2000 Sep;216(3):698-703. doi: 10.1148/radiology.216.3.r00se24698. PMID: 10966697.
- Pires FR, Sagarra R, Correa ME, Pereira CM, Vargas PA, Lopes MA. Oral metastasis of a hepatocellular carcinoma. *Oral Surg Oral Med Oral Pathol Oral Radiol Endod.* 2004;97(3):359–368. doi: 10.1016/j.tripleo.2003.09.018. [PubMed] [CrossRef] [Google Scholar]
- Kuo I-J, Chen P-R, Hsu Y-H. Gingival Metastasis of Primary Hepatocellular Carcinoma - Case report. *Tzu Chi Med J.* 2003; 18:145–147. [Google Scholar]
- Vigneul JC, Katz P. [Radiography of emergency facial injuries]. *Revue de Stomatologie et de Chirurgie Maxillo-faciale.* 1982 ;83(2-3):75-79. PMID: 6954627.



9. huichi Takinami, Hideko Yahata, Akiko Kanoshima, Michio Yamasaki, Kohsei Funaoka, Eiji Nakamura, Toshikatsu Fujiwara, Yasunori Totsuka, Hepatocellular carcinoma metastatic to the mandible, *Oral Surgery, Oral Medicine, Oral Pathology, Oral Radiology, and Endodontology*, Volume 79, Issue 5, 1995, Pages 649-654, ISSN 1079-2104, [https://doi.org/10.1016/S1079-2104\(05\)80110-6](https://doi.org/10.1016/S1079-2104(05)80110-6).
10. Maiorano, E., Piattelli, A. and Favia, G. (2000) Hepatocellular Carcinoma Metastatic to the Oral Mucosa: Report of a Case with Multiple Gingival Localizations. *Journal of Periodontology*, 71, 641-645. <https://doi.org/10.1902/jop.2000.71.4.641>
11. Fitzmaurice C, Allen C, Barber RM, Barregard L, Bhutta ZA, Brenner H, Dicker DJ, Chimed-Orchir O, Dandona R, Dandona L, et al. Global, regional, and National Cancer Incidence, mortality, years of life lost, years lived with disability, and disability-adjusted life-years for 32 Cancer groups, 1990 to 2015: a systematic analysis for the global burden of disease study. *JAMA oncology*. 2017;3(4):524–548. doi: 10.1001/jamaoncol.2016.5688. [PMC free article] [PubMed] [CrossRef] [Google Scholar]
12. Anthony PP. Hepatocellular carcinoma: an overview. *Histopathology*. 2001;39(2):109–118. doi: 10.1046/j.1365-2559.2001.01188.x. [PubMed] [CrossRef] [Google Scholar]
13. Yoshida Y, Tsukuda T, Yoshinari M, Sasaki H. Two cases of metastatic tumors to the mouth (author's transl) *Nihon Koku Geka Gakkai Zasshi*. 1976;22(4):534–540. [PubMed] [Google Scholar]
14. Kwon MJ, Ryu SH, Jo SY, Kwak CH, Yoon WJ, Moon JS, Lee HK. A case of hepatocellular carcinoma presenting as a gingival mass. *Korean J Gastroenterol*. 2016;68(6):321–325. doi: 10.4166/kjg.2016.68.6.321. [PubMed] [CrossRef] [Google Scholar]
15. Chen H-M, Wu Y-C, Wei L-Y, Chiang C-P. Metastatic hepatocellular carcinoma of the anterior palatal gingiva. *Journal of Dental Sciences*. 2014; 9:202–204. doi: 10.1016/j.jds.2014.04.004. [CrossRef] [Google Scholar]
16. Rai S, Naik R, Pai MR, Gupta A. Metastatic hepatocellular carcinoma presenting as a gingival mass. *Indian J Pathol Microbiol*. 2009;52(3):446–447. doi: 10.4103/0377-4929.55027. [PubMed] [CrossRef] [Google Scholar]
17. Huang YC, Tung CL, Lin HC. Gingival tumor as the first sign of advanced hepatocellular carcinoma on FDG PET/CT. *Clin Nucl Med*. 2009;34(2):72–73. doi: 10.1097/RLU.0b013e318192c4e6. [PubMed] [CrossRef] [Google Scholar]
18. Poojary D, Baliga M, Shenoy N, Amirthraj A, Kumar R. Adrenal insufficiency with gingival mass--an unusual presentation of hepatocellular carcinoma. *J Oral Maxillofac Surg*. 2011;69(7): e291–e293. doi: 10.1016/j.joms.2011.02.108. [PubMed] [CrossRef] [Google Scholar]
19. Terada T. Hepatocellular carcinoma metastatic to the gingiva as a first manifestation of hepatocellular carcinoma. *J Maxillofac Oral Surg*. 2011;10(3):271–274. doi: 10.1007/s12663-011-0187-z. [PMC free article] [PubMed] [CrossRef] [Google Scholar]
20. Rim JH, Moon SE, Chang MS, Kim JA. Metastatic hepatocellular carcinoma of gingiva mimicking pyogenic granuloma. *J Am Acad Dermatol*. 2003;49(2):342–343. doi: 10.1067/S0190-9622(03)00416-X. [PubMed] [CrossRef] [Google Scholar]
21. Hirshberg A, Shnaiderman-Shapiro A, Kaplan I, Berger R. Metastatic tumours to the oral cavity - pathogenesis and analysis of 673 cases. *Oral Oncol*. 2008;44(8):743–752. doi: 10.1016/j.oraloncology.2007.09.012. [PubMed] [CrossRef] [Google Scholar] 22
22. Zubler MA, Rivera R, Lane M. Hepatoma presenting as a retro-orbital metastasis. *Cancer*. 1981;48(8):1883–1885. doi: 10.1002/1097-0142(19811015)48:8<1883::AID-CNCR2820480828>3.0.CO;2-J. [PubMed] [CrossRef] [Google Scholar]
23. Hirshberg A, Leibovich P, Buchner A. Metastases to the oral mucosa: analysis of 157 cases. *J Oral Pathol Med*. 1993;22(9):385–390. doi: 10.1111/j.1600-0714.1993.tb00128.x. [PubMed] [CrossRef] [Google Scholar]
24. Wedgwood D, Rusen D, Balk S. Gingival metastasis from primary hepatocellular carcinoma. Report of a case. *Oral Surg Oral Med Oral Pathol*. 1979;47(3):263–266. doi: 10.1016/0030-4220(79)90151-8. [PubMed] [CrossRef] [Google Scholar]
25. Kanazawa H, Sato K. Gingival metastasis from primary hepatocellular carcinoma: report of a case and review of literature. *J Oral Maxillofac Surg*. 1989;47(9):987–990. doi: 10.1016/0278-2391(89)90385-6. [PubMed] [CrossRef] [Google Scholar]
26. English JC, 3rd, Meyer C, Lewey SM, Zinn CJ. Gingival lesions and nasal obstruction in an immunosuppressed patient post-liver transplantation. *Cutis*. 2000;65(2):107–109. [PubMed] [Google Scholar]
27. Papa F, Ferrara S, Felicetta L, Lavorgna G, Matarazzo M, Staibano S, De Rosa G, Troisi S, Claudio PP. Mandibular metastatic hepatocellular carcinoma: report of a case involving severe and uncontrollable hemorrhage. *Anticancer Res*. 2001;21(3C):2121–2130. [PubMed] [Google Scholar]
28. Arai R, Otsuka T, Mori K, Kobayashi R, Tomizawa Y, Sohara N, Kakizaki S, Hirokawa T, Kanda D, Nakayama H, et al. Metastasis of hepatocellular carcinoma to the supramaxillary gingiva and right ventricle.



- Hepatogastroenterology. 2004;51(58):1159–1161. [PubMed] [Google Scholar]
29. Kuga Y, Kitamura A, Kusaba I, Aketa J, Yamada N. Primary liver cancer with metastasis to the gingiva: report of a case (author's transl) *Nihon Koku Geka Gakkai Zasshi*. 1976;22(4):541–545. [PubMed] [Google Scholar]
30. Choi SJ, Kim YS, Kim NR, Jeong SW, Lee SH, Jeong JS, Ryu KH, Cha SW, Hong SJ, Ryu CB, et al. A case of hepatocellular carcinoma with metastasis to gingival mucosa. *Taehan Kan Hakhoe Chi*. 2002;8(4):495–499. [PubMed] [Google Scholar]
31. Elkhoury J, Cacchillo DA, Tatakis DN, Kalmar JR, Allen CM, Sedghizadeh PP. Undifferentiated malignant neoplasm involving the interdental gingiva: a case report. *J Periodontol*. 2004;75(9):1295–1299. doi: 10.1902/jop.2004.75.9.1295. [PubMed][CrossRef] [Google Scholar]
32. Gong LI, Zhang WD, Mu XR, Han XJ, Yao LI, Zhu SJ, Zhang FQ, Li YH, Zhang W. Hepatocellular carcinoma metastasis to the gingival soft tissues: a case report and review of the literature. *Oncol Lett*. 2015;10(3):1565–1568. doi: 10.3892/ol.2015.3422. [PMC free article] [PubMed] [CrossRef] [Google Scholar]
33. Batson OV. The function of the vertebral veins and their role in the spread of metastases. *Ann Surg*. 1940;112(1):138–149. doi: 10.1097/00000658-194007000-00016. [PMC free article] [PubMed] [CrossRef] [Google Scholar]
34. Batson OV. The vertebral system of veins as a means for cancer dissemination. *Prog Clin Cancer*. 1967; 3:1–18. [PubMed] [Google Scholar]
35. Lund BA, Soule EH, Moertel CG. Hepatocellular carcinoma with metastasis to gingival mucosa: report of case. *J Oral Surg*. 1970;28(8):604–607. [PubMed] [Google Scholar]
36. Fukai K, Takaesu Y, Maki Y. Gender differences in oral health behavior and general health habits in an adult population. *Bull Tokyo Dent Coll*. 1999;40(4):187–193. doi: 10.2209/tdcpub.40.187. [PubMed] [CrossRef] [Google Scholar]
37. Aggarwal BB, Shishodia S, Sandur SK, Pandey MK, Sethi G. Inflammation and cancer: how hot is the link? *Biochem Pharmacol*. 2006;72(11):1605–1621. doi: 10.1016/j.bcp.2006.06.029. [PubMed] [CrossRef] [Google Scholar]
38. Mantovani A. Cancer: inflammation by remote control. *Nature*. 2005;435(7043):752–753. doi: 10.1038/435752a. [PubMed] [CrossRef] [Google Scholar]
39. Llanes F, Sanz-Ortega J, Suarez B, Sanz-Esponera J. Hepatocellular carcinomas diagnosed following metastasis to the oral cavity. Report of 2 cases. *J Periodontol*. 1996;67(7):717–719. doi: 10.1902/jop.1996.67.7.717. [PubMed] [CrossRef] [Google Scholar]
40. Gleeson M, editor. Facial branches of the maxillary artery. In: *Gray's Anatomy - The Anatomical Basis of Clinical Practice*. 41st ed. London: Elsevier; 2016. p. 499.
41. Hou Y, Deng W, Deng G, Hu L, Liu C, Xu L. Gingival metastasis from primary hepatocellular carcinoma: a case report and literature review of 30 cases. *BMC Cancer*. 2019 Sep 14;19(1):925. doi: 10.1186/s12885-019-6020-7. PMID: 31521125; PMCID: PMC6744688.