ADITUM

Journal of Neurosurgery and Neurology Research

Open Access

Case Report

Tolosa Hunt Syndrome : Case Report And Literature Review

M. Bouallag [1]*, N Habchi and M Djaafer [2]

[1]Neurosurgery Department, Mustapha Pacha University Hospital, Algiers, Algeria

[1]Principal author, [2] Head of department

Article Info

Received: March 22, 2021
Accepted: March 29, 2021
Published: March 31, 2021

***Corresponding author:** M. Bouallag, Neurosurgery Department, Mustapha Pacha University Hospital, Algiers, Algeria

Citation: Bouallag M, Habchi N, Djaafer M. "Tolosa Hunt Syndrome: Case Report And Literature Review.". J Neurosurgery and Neurology Research, 2(2); DOI: http;//doi.org/03.2021/1.1012.

Abstract

Tolosa-Hunt syndrome (STH) is a painful ophthalmoplegia due to idiopathic and chronic inflammation of the superior orbital fissure or cavernous sinus. This pathology is infrequent and remains a diagnosis of exclusion. We report the case of a young patient aged 36 years without pathological history individuals admitted for the management of complete ophthalmoplegia of the right eye preceded by a slight painful exophthalmos that quickly sets in. Cerebral MRI with gadolinium injection revealed a lesion of the cavernous sinus with tumor or inflammatory appearance. An inflammatory and infectious biological assessments (VS, CRP, FNS), as well as viral serology and the autoimmunity assessment came back negative. Faced with the negativity of the examinations and the absence of a HIC syndrome (normal OF), the inflammatory cause was retained and medical treatment based on corticosteroid therapy was instituted. The course was favorable marked by a dramatic reduction in pain and oculomotor disorders. Tolosa-Hunt syndrome is an uncommon pathology and remains diagnosis exclusion.

Key Words: tolosa-hunt syndrome ; ophthalmoplegia

Introduction

Tolosa-Hunt syndrome (STH) first described in 1954 is a Painful ophthalmoplegia due to idiopathic and chronic inflammation of the superior orbital fissure or cavernous sinus resulting in facial pain and paralysis of the oculomotor nerves. This is a diagnosis of exclusion and a full exploration must be carried out. The treatment of this disease is well codified with an almost complete recovery if the management is early.

Case Report

The 36-year-old patient A.N with no particular pathological history had presented 3 months before admission to our department an ophthalmoplegia Complete of the right eye preceded by a slight painful exophthalmos quick installation.

The clinical examination found a conscious patient well oriented in time and space, with a slight exophthalmos of the non-pulsatile right eye, paralysis complete right III (ptosis, paralysis of the gaze inwards and reactive mydriasis), of the right VI (paralysis of the look out), impairment of the right VI (hypoesthesia) and II right (AV OD: 1/10 OG: 10/10 OF: normal, PEV are normal). The rest of the somatic examination is unremarkable. An inflammatory and infectious biological assessment (VS, CRP, FNS), hemoglobin Glycated as well as viral serologies and autoimmunity and thyroid tests are negative.

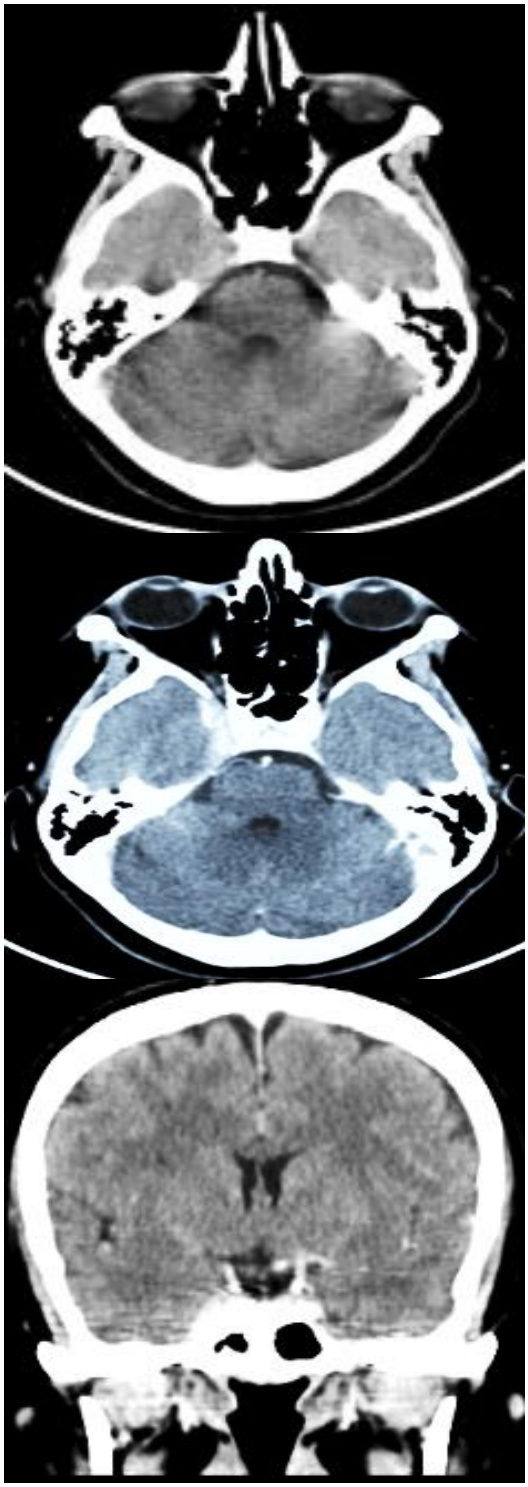

Radiological assessment

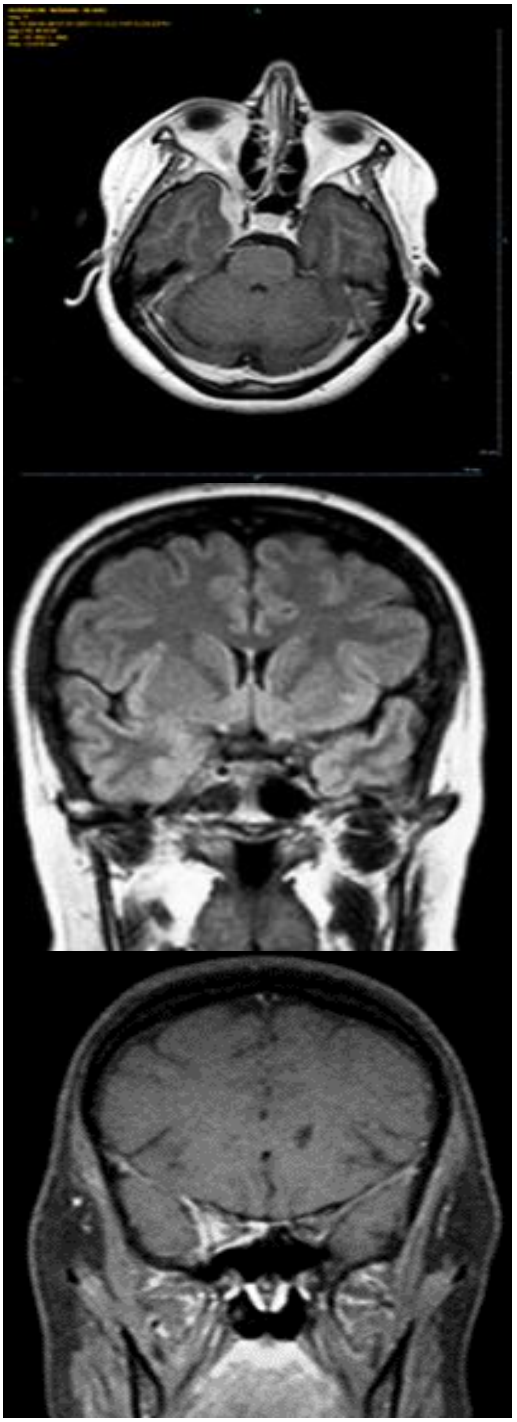

CT Cerebral SPC / APC: No particularities

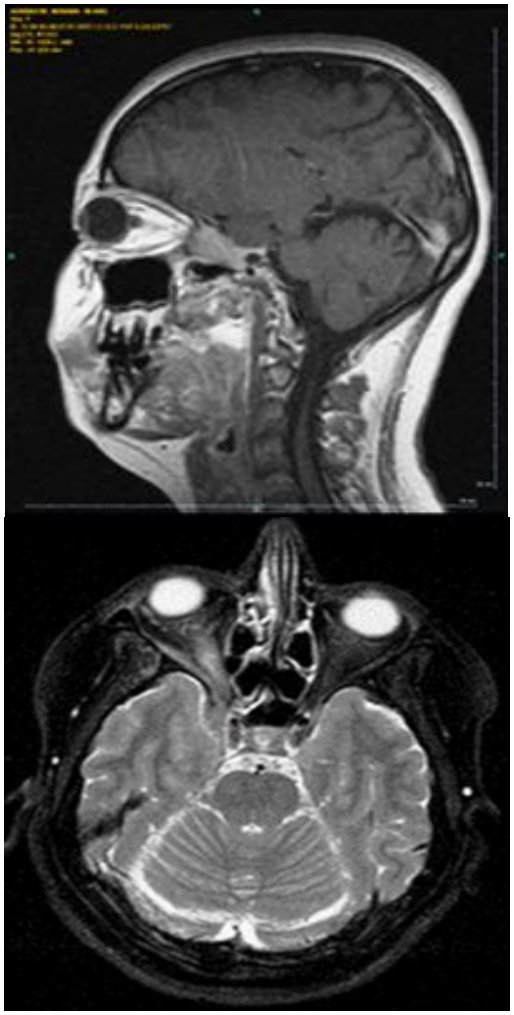

Cerebral MRI without and with injection of gadolinium chelate in axial, coronal and sagittal slices, in T1 sequences with Gadolinium, T2 showing a lesion of the cavernous sinus of Tumor or Inflammatory aspect

Faced with the negativity of biological examinations and the absence of HIC syndrome (Normal FO); the inflammatory cause was retained and corticosteroid therapy based dexamethasone, 80 mg / day was started. After 01 month of treatment, we noticed a marked improvement in the symptomatology and a dramatic regression of oculomotor disorders. Maintenance treatment with corticosteroid therapy was started with a reduced dose At 60 mg / day for 3 months.

A control brain MRI performed after 3 months of treatment showed a total disappearance of the lesion at the level of the right cavernous sinus. In front of the clinical aspect, the negativity of the biological examinations, the exclusion of another condition by brain MRI and especially the total regression of the lesion after treatment with corticosteroids; the diagnosis of Tolosa-Hunt syndrome was retained.

Brain MRI after 3 months of treatment: Total regression of the lesion

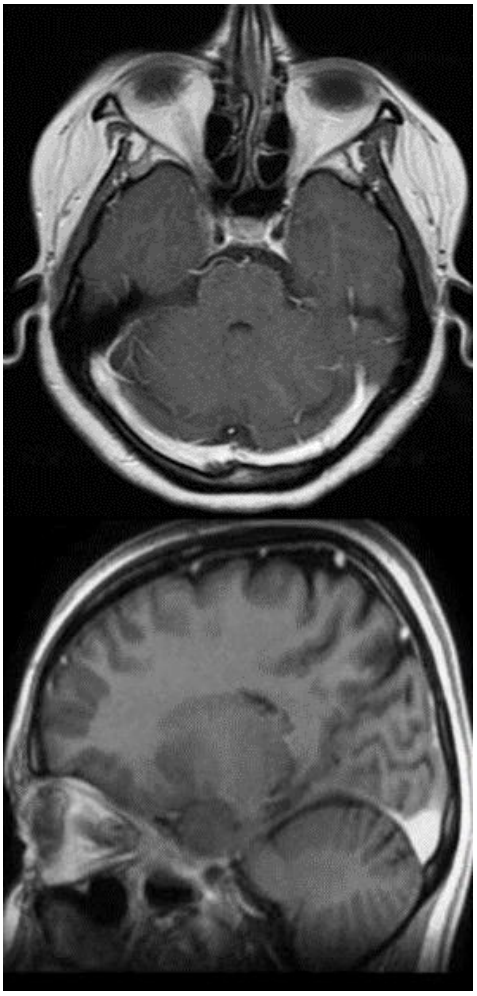

T1 with Gadolinium in axial and sagittal sections

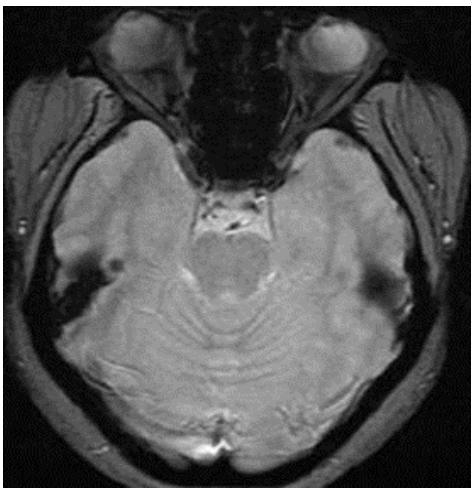

T2 with Gadolinium

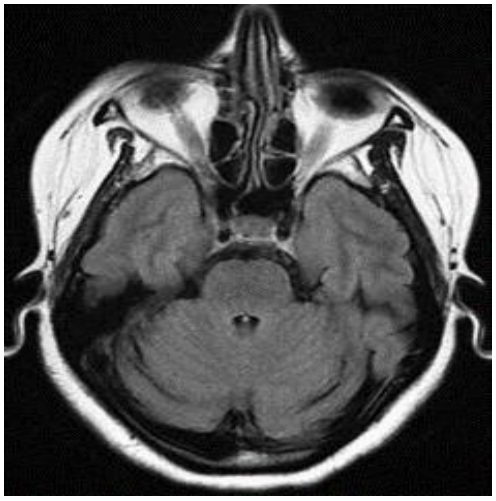

T2 FLAIR

Discussion

Tolosa Hunt syndrome is a rare syndrome, its incidence is estimated to be one case per million inhabitant per year [1]. It is characterized by a painful ophthalmoplegia, due to granulomatous inflammation idiopathic cavernous sinus. Hunt et al (1961) reported 6 similar cases with a radiological assessment without abnormalities. 5 cases of them were treated with corticosteroid therapy with spectacular results on symptomatology. Smith and Taxdal (1966) discuss for the first time Tolosa-Hunt [7]. The diagnosis of STH is currently based on very specific criteria [2, 3]: Constant, unilateral orbital pain, non-pulsatile exophthalmos, appearing in a few days; associated ophthalmoplegia corresponding to impairment of III (80%), VI (70%), IV (29%) and II (as is the case with our patient). Other nerves can be affected such as the maxillary nerves and mandibular as well as the facial nerve. The exclusion of another cause by neuroimaging and spectacular efficiency Corticosteroid therapy are criteria strongly suggestive of the diagnosis.

Conclusion

Tolosa-Hunt syndrome is painful ophthalmoplegia and paralysis oculomotor nerves. This pathology is infrequent and remains a diagnosis exclusion. Brain MRI can highlight a lesion of all kinds inflammatory or pseudo-tumor in the cavernous sinus. Its treatment consists of corticosteroid therapy with spectacular results. on symptomatology.

References

1. Iaconetta G, Stella L, Esposito M, Cappabianca P. (2005). Tolosa-Hunt syndrome extending in the cerebello-pontine angle. Cephalalgia; 25(9):746-50
2. Kline LB, Hoyt WF. (2001). The Tolosa Hunt Syndrome. J NeurolNeurosurgPsychiatry; 71(5):57782.
3. Schuknecht B, Sturm V, Huisman TA, Landau K. (2009). Tolosa-Hunt syndrome: MR imagingfeaturesin 15 patients with 20 episodes of painfulophthalmoplegia. Eur J Radiol. 69(3): 445-453
4. Mariam Anoune et al. (2015). Pan AfricanMedical Journal; 20:137
5. Headache Classification Committee of the International Headache Society (IHS). (2013). The International Classification of HeadacheDisorders, 3rd edition (beta version). Cephalalgia. 33(9):629-808
6. Cakirer S. (2003). MRI findings in Tolosa-Hunt syndrome before and after systemiccorticosteroidtherapy. Eur J Radiol. 45(2): 83-90
7. J.L. Smith and D.S.R. (1966). Taxdal, Painful opthalmoplegia: the Tolosa-Hunt Syndrome; Am J Ophthalmol 61, pp. 1466-1472.