

Sphingomonas Paucimobilis Complicating Vaginal Fluid Cultivation. A Rare Case

Chrisostomos Sofoudis^{1*}, Andria Peraki¹, Angeliki Mavroidi², Evangelia Platsouka² and Efthimios Papamargaritis¹

¹Department of Obstetrics and Gynecology, Konstandopoulio General Hospital, Athens, Greece.

²Department of Microbiology, Konstandopoulio General Hospital, Athens, Greece.

Article Info

Received: January 11, 2021

Accepted: February 18, 2021

Published: February 24, 2021

***Corresponding author:** Chrisostomos Sofoudis, Department of Obstetrics and Gynecology, Konstandopoulio General Hospital, Athens, Greece.

Citation: Sofoudis C, Peraki A, Mavroidi A, Platsouka E and Papamargaritis E, Sphingomonas Paucimobilis Complicating Vaginal Fluid Cultivation. A Rare Case. International J of Clinical Gynaecology and Obstetrics, 2(1); DOI: <http://doi.org/03.2021/1.1009>.

Copyright: © 2021 Chrisostomos Sofoudis. This is an open access article distributed under the Creative Commons Attribution License, which permits unrestricted use, distribution, and reproduction in any medium, provided the original work is properly cited.

Abstract

Sphingomonas paucimobilis represents an aerobic Gram-negative bacillus that is gaining recognition as an important human pathogen.

These species are widely distributed in both natural environment and hospitals.

They appear as opportunistic pathogen that take advantage of underlying conditions and diseases. Regardless of the clinical significance, pathogenic mechanism varies throughout current bibliography.

Aim of our study, reflects presentation of a rare case of an out-patient clinical asymptomatic, with vaginal culture positive for this rare microorganism, S. paucimobilis.

Assiduous diagnosis and therapeutic mapping consist necessary conditions of effective treatment.

Key Words: sphingomonas paucimobilis, gram-negative microorganism, vaginal culture, asymptomatic

Introduction

Sphingomonas paucimobilis depicts a glucose-no fermenting, strictly aerobic, Gram-negative bacillus that thrives in the natural environment, especially in water and soil.

At the same time, it has also been isolated from hospital settings, including hospital water systems, distilled water, dialysis fluid, nebulizers, and other respiratory therapy equipment. [1-4]

S. paucimobilis has the property of being found in low carbon environment (oligotropic). It is used for bioremediation of the environment for its ability to decompose aromatic compounds. [5]

Additionally, is characterized by catalase and oxidase activity, yellow pigment production, and slow motility with single polar flagellum. [6]

S. paucimobilis was initially reported to cause human infection in 1979. It consists an opportunistic pathogen, isolated from blood, sputum, urine, wound, bile, cerebrospinal fluid, vagina, and cervix.

Its virulence is thought to be low, and identification of the organism from clinical specimen is rare.

However, it is associated with great variety of infections, concerning community-acquired and health care-associated ones.

Specifically, literature has documented bacteremia, pneumonia, catheter related infections, meningitis, peritonitis, osteomyelitis, septic arthritis, postoperative endophthalmitis, lung empyema, splenic abscesses, urinary tract infections, and



and biliary tract infections. [7-26]

Community-acquired infection, diabetes mellitus, and alcoholism have been established as significant risk factors for primary pseudomonada paucimobilis bacteremia. [27]

Case

We present a case of a 72- year old female patient (G4, P4), with history of hypertension and hypothyroidism pharmaceutically regulated, admitted at our Department with ultrasonography depiction of uterine cavity filled with fluid presence.

Pap smear revealed no signs of malignancy. Abdominal MRI depiction confirmed fluid presence inside uterine cavity along with intense heterogeneity of uterine configuration.

Patient underwent hysteroscopic evaluation of uterine cavity along with diagnostic curettage.

During cervical penetration, a massive amount of yellow-pigmented fluid was noticed.

A cotton swab filled with suspected fluid sent for microbiologic evaluation and cultivation.

The sample from pus was cultured at 35 °C for 24-hours and yielded yellow-pigmented, smoothed, convex, non- haemolytic, oxidase- and catalase-positive colonies, growing on blood agar (Figure I) and chocolate agar plates, but not on McConkey agar plate.

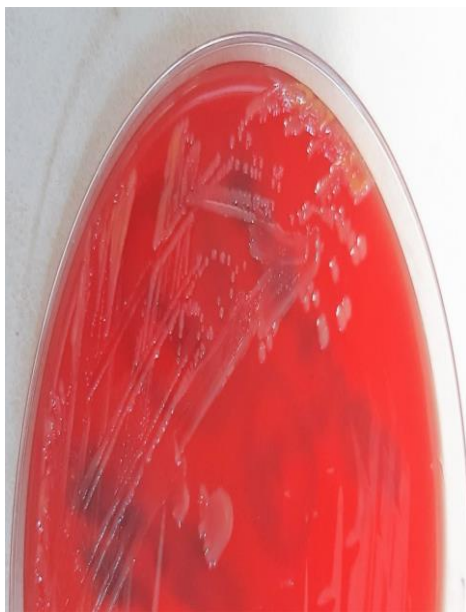

Figure I: *S. paucimobilis* culture on blood agar showing yellow-pigmented colonies.

Gram stain showed gram-negative bacilli (Figure II), which were identified as *Sphingomonas paucimobilis* by the VITEK® 2 Compact15 automated system (Biomereux, France).

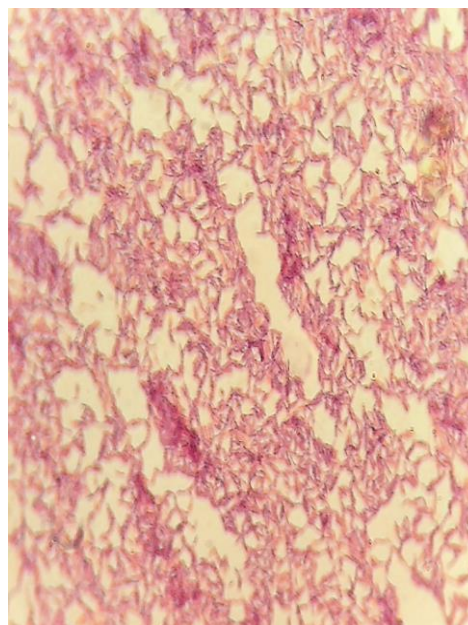


Figure II: Gram stain of the gram-negative bacillus *S. paucimobilis*.

Antibiotic susceptibility testing was performed both by the VITEK® 2 Compact15 automated system and the ETEST® method (Biomereux, France) on Mueller Hinton agar plates using an inoculum of 0.5 McFarland and a 24-hour incubation at 35 °C.

The isolate was characterised as: resistant to ceftazidime (MIC> 32µg/ml) and piperacillin/tazobactam (MIC> 16µg/ml, ciprofloxacin (MIC=1 µg/ml), susceptible-increased exposure to imipenem (MIC=2 µg/ml), and susceptible to meropenem (MIC=1 µg/ml) and amikacin (MIC<=2 µg/ml), according to the EUCAST 2020 criteria for *Pseudomonas aeruginosa*.

Hysteroscopic evaluation of uterine cavity did not reveal signs of uterine malignancy. Histologic examination of diagnostic curettage consisted areas of cervical and endometrial infection.

Patient discharged from hospital the following day in good clinical condition. She received 1g Amoxicillin and clavounic acid (Augmentin) for 10 days, 2 times per day.

Follow up with new vaginal fluid cultivation did not reveal presence of *S. paucimobilis*

Discussion

S. paucimobilis consists an aerobic, non-fermentative gram negative bacterium, widely distributed in the natural environment (e.g. water, soil).

It represents an opportunistic pathogen, considered to originate from contaminated hospital equipment or manipulation of some medical devices, causing hospital infections in immunocompromised patients and very rare in healthy persons.

Balkwill et al. reported that, although there may be certain predisposing conditions, it may not be always possible to determine the source of the infection. [28]

Lin et al. evaluated 16 cases with *S. paucimobilis* bacteremia and found a malignancy rate of 57.1% and a diabetes rate of 40.5%. [29]

So far, a variety of infections have been reported with this



microorganism, such as sepsis, septic pulmonary embolism, septic arthritis, peritonitis, and endophthalmitis.

According to Cheong et al., the most common type of infection was catheter-related infection (34.8%) followed by primary bacteremia (26.1%), continuous ambulatory peritoneal dialysis peritonitis (13.0%), and gastrointestinal infection (8.7%). [30]

Disclosure of interest: All authors declare any financial interest with respect to this manuscript.

Conclusion

S. paucimobilis represents a Gram negative bacillus, relative rare isolated in gynecologic specimens.

Assiduous therapeutic mapping consists ultimate scope, in order to avoid systemic infections and increase of patient's quality of life.

References

- Phillips G, Fleming LW, Stewart WK, Hudson S. *Pseudomonas paucimobilis* contamination in haemodialysis fluid. *J Hosp Infect* 1991; 17:70–1.
- Perez del Molino ML, Garcia-Ramos R. *Pseudomonas paucimobilis* in purified water for hospital use. *J Hosp Infect* 1989; 14:373–4.
- Lemaitre D, Elaichouni A, Hundhausen M, Claeys G, Vanhaesebrouck P, Vaneechoutte M, et al. Tracheal colonization with *Sphingomonas paucimobilis* in mechanically ventilated neonates due to contaminated ventilator temperature probes. *J Hosp Infect* 1996; 32:199–206.
- Oie S, Makieda D, Ishida S, Okano Y, Kamiya A. Microbial contamination of nebulization solution and its measures. *Biol Pharm Bull* 2006; 29:503–7.
- Coppotelli BM, Ibarrolaza A, Dias RL, Del Panno MT, BertheCorti L, Morelli IS. Study of the degradation activity and the strategies to promote the bioavailability of phenanthrene by *Sphingomonas paucimobilis* strain 20006FA. *Microb Ecol* 2010; 59:266e76.
- Yabuuchi E, Yano I, Oyaizu H, Hashimoto Y, Ezaki T, Yamamoto H. Proposals of *Sphingomonas paucimobilis* gen. nov. and comb. nov., *Sphingomonas parapaucimobilis* sp. nov., *Sphingomonas yanoikuyae* sp. nov., *Sphingomonas adhaesiva* sp. nov., *Sphingomonas capsulata* comb. nov., and two genospecies of the genus *Sphingomonas*. *Microbiol Immunol* 1990; 34:99e119
- Southern PM Jr, Kutscher AE. *Pseudomonas paucimobilis* bacteremia. *J Clin Microbiol* 1981; 13:1070–3.
- Morrison AJ Jr, Shulman JA. Community-acquired bloodstream infection caused by *Pseudomonas paucimobilis*: case report and review of the literature. *J Clin Microbiol* 1986; 24:853–5.
- Calubiran OV, Schoch PE, Cunha BA. *Pseudomonas paucimobilis* bacteraemia associated with haemodialysis. *J Hosp Infect* 1990; 15:383–8.
- Reina J, Bassa A, Llompert I, Portela D, Borrell N. Infections with *Pseudomonas paucimobilis*: report of four cases and review. *Rev Infect Dis* 1991; 13:1072–6.
- Decker CF, Hawkins RE, Simon GL. Infections with *Pseudomonas paucimobilis*. *Clin Infect Dis* 1992; 14:783–4.
- Casadevall A, Freundlich LF, Pirofski L. Septic shock caused by *Pseudomonas paucimobilis*. *Clin Infect Dis* 1992; 14:784.
- Salazar R, Martino R, Sureda A, Brunet S, Subir M, DomingoAlbs A. Catheter-related bacteremia due to *Pseudomonas paucimobilis* in neutropenic cancer patients: report of two cases. *Clin Infect Dis* 1995; 20:1573–4.
- Kristensen B, Tingsgaard LK, Ejlersen T. Self-induced bacteremia. Case report. *APMIS* 1995; 103:475–6.
- Martino R, Martínez C, Pericas R, Salazar R, Solá C, Brunet S, et al. Bacteremia due to glucose non-fermenting gram-negative bacilli in patients with hematological neoplasias and solid tumors. *Eur J Clin Microbiol Infect Dis* 1996; 15:610–5.
- Hsueh PR, Teng LJ, Yang PC, Chen YC, Pan HJ, Ho SW, et al. Nosocomial infections caused by *Sphingomonas paucimobilis*: clinical features and microbiological characteristics. *Clin Infect Dis* 1998; 26:676–81.
- Perola O, Nousiainen T, Suomalainen S, Aukee S, Kärkkäinen UM, Kauppinen J, et al. Recurrent *Sphingomonas paucimobilis*-bacteraemia associated with a multi-bacterial water-borne epidemic among neutropenic patients. *J Hosp Infect* 2002; 50:196–201.
- Al-Anazi KA, Abu Jafar S, Al-Jasser AM, Al-Shangeeti A, Chaudri NA, Al Jurf MD, et al. Septic shock caused by *Sphingomonas paucimobilis* bacteremia in a patient with hematopoietic stem cell transplantation. *Transpl Infect Dis* 2008; 10:142–4.
- Kilic A, Senses Z, Kurekci AE, Aydogan H, Sener K, Kismet E, et al. Nosocomial outbreak of *Sphingomonas paucimobilis* bacteremia in a hemato/oncology unit. *Jpn J Infect Dis* 2007; 60:394–6.
- Charity RM, Foukas AF. Osteomyelitis and secondary septic arthritis caused by *Sphingomonas paucimobilis*. *Infection* 2005; 33:93–5.
- Adams WE, Habib M, Berrington A, Koerner R, Steel DH. Postoperative endophthalmitis caused by *Sphingomonas paucimobilis*. *J Cataract Refract Surg* 2006; 32:1238–40.
- Phillips G, Fleming LW, Stewart WK. *Pseudomonas paucimobilis* peritonitis in a patient on CAPD successfully treated with ciprofloxacin and netilmicin. *Eur J Clin Microbiol Infect Dis* 1990; 9:630–1. 23.
- Ensminger SA, Wright RS, Baddour LM, Afessa B. Suspected ventilator-associated pneumonia in cardiac patients admitted to the coronary care unit. *Mayo Clin Proc* 2006; 81:32–5.
- Glupczynski Y, Hansen W, Dratwa M, Tielemans C, Wens R, Collart F, et al. *Pseudomonas paucimobilis* peritonitis in patients treated by peritoneal dialysis. *Clin Microbiol* 1984; 20:1225–6.
- Studemeister AE, Beilke MA, Kirmani N. Splenic abscess due to *Clostridium difficile* and *Pseudomonas paucimobilis*. *Am J Gastroenterol* 1987; 82:389–90.
- Cover TL, Appelbaum PC, Aber RC. *Pseudomonas paucimobilis* empyema after cardiac transplantation. *South Med J* 1988; 81:796–8
- Han-Siong Toh a, Hung-Tze Tay b, Wei-Khie Kuar b, Tzu-Chieh Weng a, Hung-Jen Tang a, Che-Kim Tan b, Risk factors associated with *Sphingomonas paucimobilis* infection, *Journal of Microbiology, Immunology and Infection* (2011)44, 289-295



28. Balkwill DL, Frederikson JK, Romine MF: Sphingomonas and related genera in Dworkin M, Falkow S, Rosenberg E, Schleifer KH, Stackebrand R (eds): The Prokaryotes: An Electronic Revolving Resource for the Microbiological Community, 3rd ed. New York: Springer Verlag, 2006, pp605-629
29. Lin JN, Lai CH, Chen YH, Lin HL, Huang CK, Chen WF, et al.: Sphingomonas paucimobilis bacteremia in humans: 16 case reports and a literature review. J Microbiol Immunol Infect 43: 35-42, 2010
30. Cheong HS, Wi YM, Moon SY, Kang CI, Son JS, Ko KS, et al. Clinical features and treatment outcomes of infections caused by Sphingomonas paucimobilis. Infect Control Hosp Epidemiol 2008;29:990.