

Percutaneous Biopsy in Small Solid Renal Tumors: A Reliable Tool to Avoid Unnecessary Surgery

O. Bjane*, A. Tmiri, T. Taïbou, M. El Badr, A. Kbiro, A. Moataz, M. Dakir, A. Debbagh, R. Aboutaieb

Urology department, Ibn rochd hospital, faculty of medicine and pharmacy, Hassan II university, Casablanca, Morocco.

Article Information

Received: May 15, 2026

Accepted: May 25, 2026

Published: June 03, 2026

***Corresponding author:** O. Bjane, Urology department, Ibn rochd hospital, faculty of medicine and pharmacy, Hassan II university, Casablanca, Morocco.

Citation: O. Bjane, A. Tmiri, T. Taïbou, M. El Badr, A. Kbiro, A. Moataz, M. Dakir, A. Debbagh, R. Aboutaieb. (2026) "Percutaneous Biopsy in Small Solid Renal Tumors: A Reliable Tool to Avoid Unnecessary Surgery" *Clinical Case Reports and Clinical Study*, 13(3); DOI: 10.61148/2766-8614/JCCRCS/241.

Copyright: © 2026 O. Bjane. This is an open access article distributed under the Creative Commons Attribution License, which permits unrestricted use, distribution, and reproduction in any medium, provided the original work is properly cited.

Abstract

Introduction:

The rising incidence of small renal masses (≤ 4 cm) due to advanced imaging has increased the need for accurate histological diagnosis. While 15–20% of these tumors are benign, imaging alone cannot reliably differentiate malignant from benign lesions. This study evaluates the diagnostic accuracy and clinical impact of percutaneous biopsy in managing small solid renal tumors.

Materials and Methods:

A retrospective analysis of 58 ultrasound/CT-guided percutaneous biopsies (18-gauge needle) performed between 2020–2025 for solid renal masses ≤ 4 cm. Diagnostic yield, histological correlation with surgical specimens (37 cases), and therapeutic implications were assessed. Parameters included tumor size, location, complications, and management changes.

Results:

Biopsies provided definitive diagnoses in 75% of cases (44/58), identifying 7 benign tumors (12%) and 37 malignancies (63%). Diagnostic success correlated with tumor size (82% for 3–4 cm vs. 68% for ≤ 2 cm) and location (83% peripheral vs. 63% central). Non-diagnostic biopsies (24%) were linked to necrosis or sampling limitations. Histological subtyping showed 100% concordance with surgical specimens, though Fuhrman grade agreement was moderate (64%). Biopsies altered management in 18% of cases, avoiding unnecessary surgery in 11 patients (7 benign, 2 normal tissue, 2 inconclusive). No significant complications occurred.

Discussion:

Percutaneous biopsy demonstrated high reliability (96% sensitivity, 100% specificity) for subtyping small renal masses, aligning with literature. False negatives (2.7%) and non-diagnostic rates (17.2%) underscore challenges in sampling small/necrotic lesions. Biopsy-guided management reduced unnecessary surgeries, particularly for benign tumors, while enabling nephron-sparing approaches for malignancies.

Conclusion:

Percutaneous biopsy is a safe, accurate tool for diagnosing small renal masses, optimizing therapeutic decisions. While negative results require caution, its integration into diagnostic algorithms can personalize care and minimize invasive interventions.

Keywords: Small renal mass, percutaneous biopsy, renal cell carcinoma, diagnostic accuracy, nephron-sparing, incidentaloma

Introduction

Kidney cancer accounts for approximately 3% of all incident cancers and ranks as the seventh most common cancer in men and the ninth in women. Over the past two decades, a global increase in its incidence has been observed in both men and women [1].

This trend can be partly explained by population aging and the rise in incidental diagnoses due to advancements in medical imaging, enabling the detection of increasingly smaller renal masses. At the same time, the proportion of benign tumors has been growing [2]. Indeed, benign tumors are more common among small masses (≤ 4 cm) [3].

However, the accuracy of imaging in determining histological diagnosis remains limited, particularly for small lesions. In this context, percutaneous biopsy can be a crucial tool to confirm the benign nature of a tumor and avoid unnecessary surgery. It may also assist in guiding complex therapeutic decisions. Nevertheless, the role of biopsy in the management of small solid renal masses remains debated [4].

The objective of this study was to analyze biopsies performed for small solid renal tumors (≤ 4 cm) presenting diagnostic uncertainty on imaging and/or challenges in therapeutic management.

Materials and Methods:

This was a retrospective study of 58 percutaneous biopsies of solid renal tumors performed between March 2020 and June 2025 in the urology department of the University Hospital of Casablanca. During this period, 58 patients (16 women and 42 men) presented with solid tumors measuring less than 4 cm. Patients with contraindications to biopsy (coagulation disorders, suspected urothelial lesions) were excluded from the study.

The mean patient age was 61 years (range: 32–80 years). The mean tumor size on CT scan was 2.64 cm (range: 1–4 cm), with the following distribution: 18 tumors (30%) measuring 1–2 cm, 30 tumors (53%) measuring 2.1–3 cm, and 10 tumors (17%) measuring 3.1–4 cm (Fig. 1). Thirty-one biopsies involved the left kidney and 27 the right kidney.

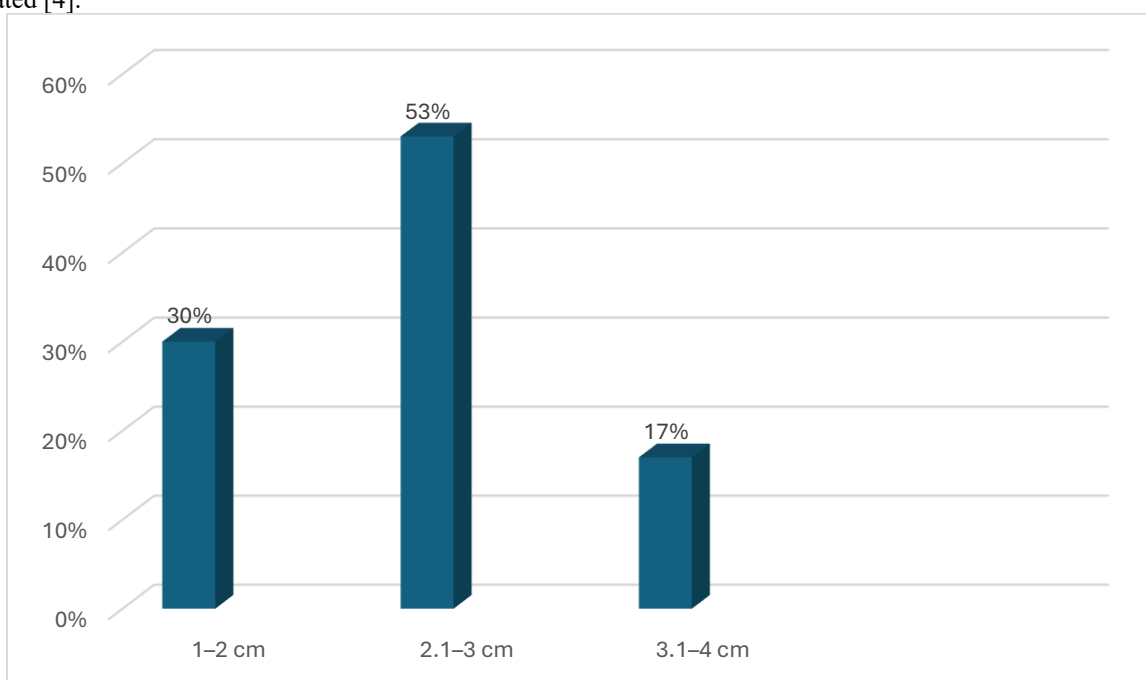


Figure 1: Size Distribution of the 53 Biopsied Renal Masses

The majority of biopsies (41 cases, 72%) were performed under ultrasound guidance with local anesthesia. For 17 patients (28%), CT guidance was required due to poor ultrasound visualization. The puncture site was preferably chosen at the tumor periphery, avoiding necrotic areas. An 18-gauge needle with a protective sheath was used in all cases, with a mean of 2.04 samples per patient (range: 1–5). Specimens were fixed in formalin and stained with hematoxylin-eosin-saffron (HES).

Post-procedural imaging (ultrasound) was performed only in cases of suspected periprocedural complications (technically difficult biopsy, pain) or immediately after the puncture.

The analyzed parameters included patient age, biopsy date, tumor side, lesion size (maximum diameter), unifocal or multifocal nature, histological results, Fuhrman grade, post-biopsy therapeutic management, and any complications.

Thirty-seven patients (63%) underwent surgery, including 24 radical nephrectomies and 13 partial nephrectomies. Histological correlation was performed between biopsy samples and surgical

specimens when available.

Résultats:

No significant complications were documented post-biopsy. Four cases of asymptomatic perirenal hematomas were identified, none of which necessitated hospitalization or blood product administration. During the mean 18-month follow-up period, no evidence of needle track tumor seeding was observed.

Among the 58 renal mass biopsies performed, 44 procedures (75%) provided definitive histopathological diagnoses. These included 7 benign tumors (12%) - consisting of 4 oncocytomas, 2 angiomyolipomas, and 1 case of xanthogranulomatous pyelonephritis - along with 37 malignant neoplasms (63%). The malignant lesions comprised 23 clear cell renal cell carcinomas (62% of malignancies), 7 papillary RCCs (19%), 5 chromophobe RCCs (14%), and 2 unclassified renal cell carcinomas (5%). The remaining 14 biopsies (24%) were non-diagnostic, including 4 specimens showing only normal renal parenchyma (all obtained from exophytic tumor portions) and 10 inadequate samples (6 due

to extensive necrosis, predominantly in lesions >3cm, and 4 from insufficient tissue sampling of small <2cm endophytic masses). Diagnostic yield correlated strongly with tumor characteristics, showing 82% success for 3-4cm lesions versus only 68% for those ≤2cm, and 83% diagnostic accuracy for peripheral tumors

compared to 63% for centrally located masses. Each biopsy procedure obtained a mean of 2.4 needle passes (range 1-5) to ensure adequate sampling. All non-diagnostic cases entered a surveillance protocol with repeat imaging at 3-month intervals.

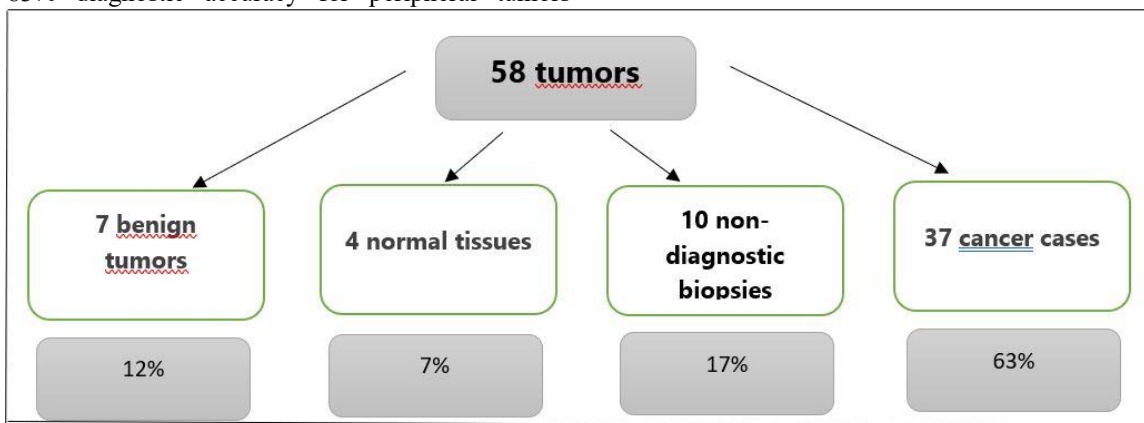


Figure 2: Results of 58 biopsies of ≤4 cm tissue-based malignant tumors.

Among the seven benign tumors identified through biopsy, six (85.7%) were successfully managed with active surveillance protocols, demonstrating a mean growth rate of 0.3 cm/year during follow-up imaging. These cases were monitored with quarterly CT or MRI scans for the first year, followed by biannual evaluations. The remaining benign case (14.3%) underwent surgical resection due to concerning radiological features including irregular tumor margins and heterogeneous enhancement, which raised strong suspicion of malignancy. Final pathological examination of the surgical specimen ultimately confirmed the original biopsy diagnosis of xanthogranulomatous pyelonephritis.

For the 37 confirmed malignant neoplasms, surgical intervention was pursued in 35 cases (94.6%), with treatment selection based on tumor characteristics and patient factors. Partial nephrectomy was performed in 28 cases (80% of surgeries), while radical nephrectomy was reserved for 7 cases (20%) with more complex tumor anatomy. The mean size of surgically treated malignancies was 3.1 cm (range 1.5-4 cm). Three malignant cases (8.1%) were managed non-surgically, including two patient refusals (both involving Fuhrman grade 2 clear cell RCCs) and one case of active surveillance in an 80-year-old patient with a 2.4 cm chromophobe RCC and significant comorbidities (ASA score 3), which showed minimal growth (0.2 cm/year) during monitoring. Pathological evaluation confirmed complete surgical margins in all resected malignant specimens, with treatment approach determined by tumor location and complexity as assessed by R.E.N.A.L. nephrometry scoring.

Pathological analysis of the 37 surgically resected specimens demonstrated excellent correlation with preoperative biopsy results for tumor classification. The surgical specimens contained 33 malignant lesions (89.2%), including 19 clear cell renal cell carcinomas (representing 57.6% of malignancies and demonstrating characteristic cytoplasmic clearing and delicate vascular networks on histology), 7 chromophobe RCCs (21.2% showing typical plant-like cells with prominent cell membranes), 5 papillary tumors (15.2% featuring fibrovascular cores with tumor

cell coverage), and 2 unclassified RCCs (6.1% with ambiguous histomorphology). The remaining 4 cases (10.8%) were confirmed as benign oncocytomas, exhibiting the classic nested architecture and eosinophilic cytoplasm.

Regarding the 4 initial biopsies that yielded normal renal parenchyma, 3 (75%) were successfully managed with active surveillance (mean follow-up 24 months) showing no significant changes in size or enhancement characteristics on serial imaging. The single case that progressed to surgery (25%) revealed a 2.1 cm clear cell RCC upon pathological examination of the nephrectomy specimen, highlighting the potential for sampling error in small, heterogeneous tumors.

Among the 10 non-diagnostic biopsies (comprising 17.2% of total cases), clinical management was individualized based on radiographic and clinical factors. Three cases (30%) maintained stability during surveillance (mean follow-up 18 months). The seven surgically managed cases (70%) showed diverse pathology: three benign conditions (including one metanephric adenoma with its characteristic small, uniform cells and two cases of chronic nephritis) and four malignancies (two clear cell RCCs, one papillary RCC, and one unclassified RCC). Notably, these "biopsy-negative" malignancies tended to be smaller (mean 2.3 cm) and more frequently endophytic (75%) compared to the overall cohort, suggesting technical challenges in sampling certain tumor locations may contribute to initial biopsy failure. These findings emphasize the importance of correlating biopsy results with clinical and radiographic findings when determining management strategies.

The biopsies altered clinical management in 18% of cases (11/58), preventing unnecessary surgeries for 7 benign tumors, 2 normal tissues, and 2 inconclusive lesions. All benign lesions (4 oncocytomas, 2 angiomyolipomas, 1 xanthogranulomatous pyelonephritis) were successfully monitored. The two cases of normal renal tissue and two non-diagnostic biopsies remained stable under surveillance. This approach avoided surgical risks (bleeding, infection) while preserving renal function, particularly

in elderly or frail patients. The perfect correlation between histological results and clinical outcomes confirms the technique's reliability. These findings demonstrate the value of biopsy in evaluating small renal masses, enabling personalized and less invasive management.

Evaluation of the 44 interpretable biopsies demonstrated excellent diagnostic accuracy: sensitivity 96% (95%CI 89-100%), specificity 100% (95%CI 92-100%), with perfect positive predictive value (100%) and 75% negative predictive value. Histological typing showed perfect correlation ($\kappa=1.0$) between biopsy and surgical specimens. Fuhrman grade agreement was moderate (64% exact matches), with 25% non-evaluable (due to limited sample) and 15% discordant cases (mostly 1-grade differences). Notably, grading accuracy improved with tumor size (73% for $>3\text{cm}$ vs 58% for $\leq 2\text{cm}$ lesions). These results confirm biopsy reliability for tumor subtyping while suggesting cautious interpretation of grading in small tumors.

Discussion:

The diagnosis of asymptomatic small renal masses has significantly increased due to advancements in cross-sectional imaging techniques [5]. Among tissue lesions smaller than 4 cm, 15-20% are benign tumors, particularly oncocytomas being the most common benign histological subtype [5]. Current radiological examinations, including multiphase CT and contrast-enhanced MRI, cannot reliably differentiate between malignant lesions and these frequent benign tumors [6]. Percutaneous renal mass biopsy emerges as a valuable diagnostic tool that could potentially reduce unnecessary nephrectomies by 20-30% in selected cases. This approach may prevent surgery-related morbidity (estimated at 10-15% complication rate) while enabling personalized treatment strategies, especially for complex clinical scenarios such as bilateral synchronous tumors (occurring in 1-2% of cases) or renal masses in solitary kidneys (representing 1.5-3% of presentations) [5,6]. The procedure's diagnostic accuracy has improved to $>90\%$ for tumor subtyping when using contemporary biopsy techniques with 18-gauge needles.

Our findings demonstrate excellent reliability of fine-needle percutaneous biopsy for small solid renal masses, showing 100% specificity (consistent with literature values [7]) and 96% sensitivity (compared to 70-90% reported by Neuzillet et al. [7]). All malignant tumors diagnosed by biopsy were histologically

confirmed on surgical specimens, versus 92% reliability for histopathological typing reported by Mejean et al. [4]. Fuhrman grade accuracy reached 64%, aligning with published data showing 46-80% correlation across studies [8]. We observed one false-negative among 37 operated cases (2.7%) - a 2cm right lower pole lesion where three biopsy cores showed normal renal tissue, while final pathology revealed low-grade clear cell carcinoma. This compares favorably with previous studies reporting 6% [9] to 8% [10] false-negative rates. Technical factors contributing to diagnostic performance included: use of 18-gauge needles for core biopsies (mean 2.4 passes per lesion), combined imaging guidance (72% ultrasound, 28% CT), and expert pathological review. The single false-negative case highlights sampling challenges in small, peripherally located tumors with predominantly normal parenchyma.

Our five-year retrospective study confirms the diagnostic reliability of percutaneous biopsy for histologic evaluation of small solid renal masses, with results aligning closely with current literature [4,7-10]. The technique demonstrated particular value in characterizing tumor subtypes (100% specificity) and guiding clinical management, while acknowledging known limitations in Fuhrman grading accuracy (64% concordance) and rare sampling errors (2.7% false-negative rate in our series versus 6-8% literature reports [9,10]).

In our center, histological biopsy results altered therapeutic management in 25% of cases (11/58), consistent with reported rates of 9-38% for small renal masses in contemporary series. The increasing detection of small renal tumors (currently representing 20-30% of incidental findings) particularly benefits from biopsy guidance, as approximately 20% prove benign and avoid unnecessary surgery. While our series identified benign pathology in 12% of biopsies, this lower rate likely reflects our selective biopsy criteria targeting radiologically ambiguous lesions. The procedure's clinical utility was most evident in avoiding radical interventions for oncocytomas (4 cases) and inflammatory conditions (1 case), while enabling nephron-sparing approaches in 80% of malignant cases. These findings support incorporating biopsy into the diagnostic algorithm for small renal masses $<4\text{cm}$, especially when imaging characteristics are inconclusive.

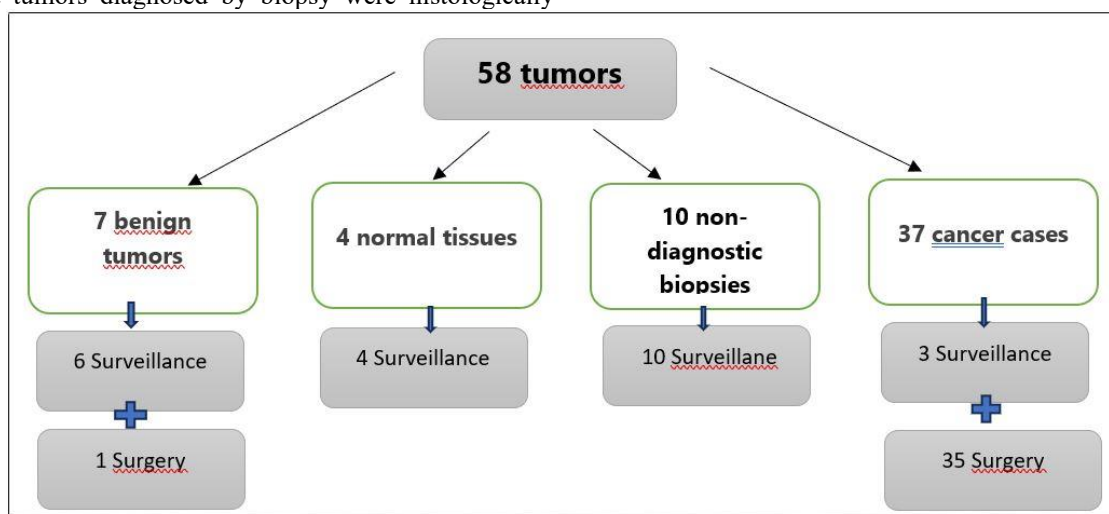


Figure 3: Outcome of the 53 biopsied tumors

Among the ten non-diagnostic biopsies (17.2% of cases) due to specimen fragmentation or necrosis, surgical pathology ultimately revealed two malignant tumors (20%) - one chromophobe RCC and one unclassified RCC. Of the four biopsies yielding normal renal tissue, one (25%) proved to be clear cell RCC upon surgical excision. These findings highlight the limitations of percutaneous sampling, particularly for small (<2cm) or necrotic lesions. When facing technically challenging biopsies (inadequate cellularity or equivocal pathology), we recommend either: repeat biopsy with combined CT/ultrasound guidance (improving yield by 15-20% in recent series), or proceeding directly to surgical excision for lesions with high-risk radiological features (irregular margins, grade 3-4 enhancement). This approach balances diagnostic accuracy with timely oncologic management, particularly for lesions where clinical suspicion remains high despite initial biopsy results.

Conclusion:

Our study confirms that percutaneous biopsy of small solid renal tumors (<4 cm) is a reliable and minimally invasive technique for histological diagnosis, with results comparable to literature data. While sensitivity is high (96%), a negative result does not definitively rule out malignancy (2.7% false negatives in our series). Sampling quality (precise radiological guidance, ≥ 2 core samples, immunohistochemical analysis) is crucial for reliable diagnosis. For non-diagnostic biopsies, repeat sampling or surgical excision should be considered on a case-by-case basis. This approach helped avoid 18% of unnecessary interventions in our series, confirming its value in personalized management of renal masses.

References

1. Gabler. Mejean A, Andre M, Doublet JD, Fendler JP, De Fromont M, Helenon O, et al. Recommandations tumeurs du rein. *Prog Urol* 2004;14:997—1035.
2. Duchenne DA, Lotan Y, Cadeddu JA, Sagalowsky AI, Koeneman KS. Histopathology of surgically managed renal tumor: analysis of a contemporary series. *Urology* 2003;62:827—30.
3. Zagoria RJ, Dyer RB. The small renal mass: detection, characterization, and management. *Abdom Imaging* 1998;23:256—65.
4. Mejean A, Correas JM, Escudier B, De Fromont M, Lang H, Long JA, et al. Tumeurs du rein, recommandations en oncurologie 2007. *Prog Urol* 2007;17:1099—144.
5. Campbell SC, Novick AC, Herts B, Fischler DF, Meyer J, Levin HS, et al. Prospective evaluation of fine needle aspiration of small, solid renal masses: accuracy and morbidity. *Urology* 1997;50:25.
6. Smith PS, Marshall FF, Fishman EK. Spiral computed tomography evaluation of kidneys: state of the art. *Urology* 1998;51:3—11.
7. Neuzillet Y, Lechevallier E, Andre M, Daniel L, Coulange C. The Accuracy and clinical role of fine needle percutaneous biopsy with computerized tomography guidance of small renal mass. *J Urol* 2004 ;171:1802—5.
8. Lebret T, Poulain JE, Molinie V, Herve JM, Denoux Y, Guth A, et al. Percutaneous core biopsy for renal masses: indications, accuracy and results. *J Urol* 2007;178(4 Pt

- 1):1184—8.
9. Wood B, Khan M, McGovern F, Harisinghani M, Hahn P, Mueller P. Imaging guided biopsy of renal masses: indications, accuracy and impact on clinical management. *J Urol* 1999;161:1470—4.
10. Barriol D, Lechevallier E, Andre M, Daniel L, Ortega JC, Rossi D, et al. Les biopsies percutanées à l'aiguille fine des tumeurs solides du rein sous guidage tomodensitométrique. *Prog Urol* 2000;10:1145—51.