



## Efficacy of Topical Cetirizine 1% in Treatment of Androgenic Alopecia: Clinical and Dermoscopic Evaluation

**Running title: Topical Cetirizine 1% in Treatment of AGA.**

Sara Ahmed Galal<sup>1\*</sup>, Wafaa Afify Mahmoud<sup>2</sup> and Noha Adel Kamal Ahmed<sup>3</sup>

<sup>1</sup>Assistant Professor of Dermatology and Venereology Department, Faculty of Medicine (Girls), Al-Azhar University, Cairo, Egypt.

<sup>2</sup>Professor of Dermatology and Venereology Department, Faculty of Medicine (Girls), Al-Azhar University, Cairo, Egypt.

<sup>3</sup>Dermatology department, ministry of Health.

### Article Info

**Received:** July 18, 2024

**Accepted:** July 26, 2024

**Published:** July 30, 2024

**\*Corresponding author:** Sara Ahmed Galal, Assistant Professor of Dermatology and Venereology Department, Faculty of Medicine (Girls), Al-Azhar University, Cairo, Egypt.

**Citation:** Sara Ahmed Galal, Wafaa Afify Mahmoud and Noha Adel Kamal Ahmed. (2024) "Reducing Scar and Post Inflammatory Acne by Using Daily Skincare Regimen." Journal of Dermatology and Venereology, 2(1); DOI: DOI: 10.61148/JDV/008

**Copyright:** © 2024 Sara Ahmed Galal. This is an open access article distributed under the Creative Commons Attribution License, which permits unrestricted use, distribution, and reproduction in any medium, provided the original work is properly cited.

### Abstract:

**Background:** Androgenetic alopecia (AGA) is a form of non-scarring scalp hair loss that affects more than 50% of males. Prostaglandins would have an important role in hair growth and their action is variable according to their class. Based on these and the scarce studies that suggest the effectiveness of cetirizine on AGA we carried out this study.

**Aim of Work:** Dermoscopic evaluation of the efficacy of topical cetirizine 1 % in male patients with androgenetic alopecia.

**Materials and methods:** A prospective study was carried out on 50 Egyptian male patients treated with topical cetirizine 1% formula once daily. The clinical and dermoscopic examination was done before, during, and after treatment to evaluate the response.

**Results:** There was a significant increase in the number of terminal hairs, a decrease in the number of vellus hair, and hair diameter diversity after treatment. There was mild to good photographic improvement.

**Conclusion:** Topical cetirizine 1 % had a promising effect in the treatment of AGA in men after 4 months of treatment. It also is having an excellent safety profile which could be an excellent option in the near future for the patients.

**Keywords:** androgenetic alopecia (aga); cetirizine; prostaglandins (pgds); dermoscopy

### Introduction:

Androgenetic alopecia (AGA) is a common condition affecting both males and females of all ages. Although it is not a life-threatening condition, it has a negative psychological impact.[1]

Cetirizine is a second-generation histamine H1 receptor blocker, which is used for many conditions. It is safe and well-tolerated. [2] Cetirizine inhibits the release of prostaglandin D2 on the other hand it stimulates the production of prostaglandin E2. [3] PGD2 has a negative effect on the hair, leading to follicular miniaturization. [4]

Genetic factors and Testosterone are the main accused of baldness occurrence. [5] However, Androgenetic alopecia is associated with some degree of inflammation. [6] Micro-inflammation around the hair follicles can cause Follicle miniaturization and worsen AGA. Cetirizine has an anti-inflammatory effect which can be beneficial in the treatment of AGA. [7]

In this regard inhibition of PGD2 using cetirizine may be a promising treatment target and a clue for the pathogenesis of AGA.

As there are few studies, that evaluate the role of topical cetirizine in the treatment of AGA. We aimed in the present study to evaluate the effect of topical cetirizine 1% in men with AGA both clinical and by dermoscope.

### Patients and Methods:

This prospective clinical trial was conducted on 50 patients. Cases were recruited from the Outpatient clinic during the period from March 2017 to December 2018. Informed written consent was obtained from all patients. The approval from the research ethics committee of the faculty of medicine, Al-Azhar University was also obtained.

### Patients:

Male patients with different grades AGA, their ages ranged from 20-42 years. We exclude females and patients with other causes of hair loss. Patients with systemic diseases or dermatological conditions which may contribute to hair loss were also excluded. We also excluded patients with a history of current or previous treatment for hair loss 1 year ago.

### Methods:

Patients were subjected to the following items: careful history was taken. History of systemic illnesses or dermatological disorders. History of previous treatment of AGA if present: duration, when stopped, result, and side effects.

The patients were carefully evaluated and grading according to the Norwood- Hamilton Classification into 7 grades. [8]

Routine investigations were done such as complete blood count, random blood sugar, renal and liver function test, and thyroid function test to exclude, thyroid disorder, anemia, and systemic illness.

### Composition of cetirizine 1% formula:

Every 1 ml of solution contains: 10 mg cetirizine dihydrochloride, 450 mg sorbitol, 1.35 methyl parahydroxy benzoate, 0.15 mg propyl parahydroxy benzoate.

### Treatment Technique:

Topical cetirizine 1% lotion was applied at the frontal area of the vertex. Each of our patients received the required dose during the treatment window (1ml/day for 4 months). During our monthly sessions with our patients, we were evaluating the treatment response both clinically and by dermoscopy.

### Assessments:

Dermoscopic and Photographic assessments were done before treatment, during treatment for 4 months, and two months after the

stoppage of the drug.

### I. Photographic Assessment:

Pictures were taken every month for 2 areas of the scalp (frontal and vertical), using (Samsung ES70digital camera)

The degree of improvement was assessed according to the grade of change in Hamilton-Noorwood classification types as follows:

- Mild and moderate improvement means there is an improvement but still within the same grade.
- Good improvement if there is a change in the grade of AGA.
- Excellent: if improvement results in changing the type to type I or to normal.

### II. Dermoscopic Assessment:

The study was also assessed by dermoscopy (DermLite® IV) at baseline, during treatment, and after 2 months for signs of AGA: Total hair density (D), Vellus hair density (VD), and Terminal hair density (TD)

Two pictures were taken before each session one for the frontal and the other for the vertical area (12 cm and 18 cm from interciliary space). From the dermoscopic images obtained, we counted the total number of hair and calculated the percentage of Vellus hair (VD) and Terminal hair (TD).

Variations in hair shaft diameter (%), the number of follicles with a single hair, number of perifollicular halo, yellow dots, and black dots were also counted.

### III. Patient Self-Assessment:

Every session the patients were asked to assess the degree of improvement in hair density, hair thickness, rate of hair fall, and color and brightness of hair (hair quality).

Assessment for the degree of improvement in the 4 parameters was done by giving numeric values from -1 to 4 (-1 means worse, 0 means no change, 1 means mild improvement, 2 means moderate improvement, 3 means good improvement, and 4 means excellent improvement).

The patients were asked about any side effects noticed every session as regards pain, headache, itching, and puffed eye.

### Statistical Analysis:

Data were collected, revised, coded, and entered into the IBM computer, statistical package for social science (IBM SPSS) version 20.

Qualitative data were presented as numbers and percentages while quantitative data were presented as mean, standard deviation (SD), and ranges.

The comparison of quantitative data and parametric distribution between more than two groups were done by using one-way ANOVA.

Spearman correlation coefficients were used to assess the correlation between two quantitative parameters in the same group. The confidence interval was set to 95% and the margin of error accepted was set to 5%. So, the p-value was considered significant if  $P < 0.05$  and highly significant  $P < 0.01$ .

## Results:

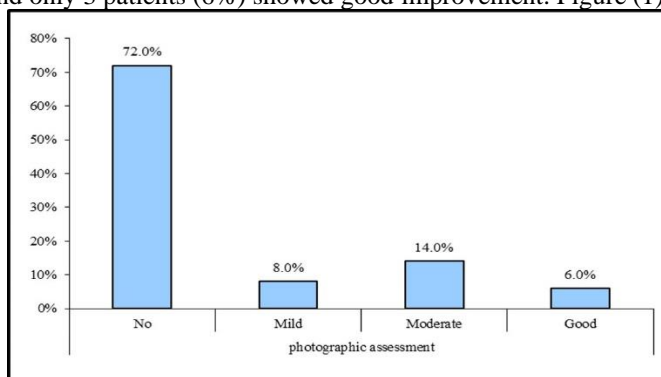
The present study included 50 male patients with androgenetic alopecia that have applied topical cetirizine 1% lotion. Their age ranged from (22-42) years with a mean  $\pm$ SD (29.1 $\pm$ 4.57). The grade of AGA was classified according to Hamilton-Noorwood classification to 7 grades Table (1)

		No. = 50
Age	Mean $\pm$ SD	29.10 $\pm$ 4.57
	Range	22 – 42
$\leq$ 30		33 (66.0%)
$>$ 30		17 (34.0%)
Duration of illness (years)	Mean $\pm$ SD	7.40 $\pm$ 4.46
	Range	2 – 20
Family history	No	19 (38.0%)
	Yes	31 (62.0%)
Grade	I	6 (12.0%)
	II	11 (22.0%)
	III	15 (30.0%)
	IV	8 (16.0%)
	V	5 (10.0%)
	VI	3 (6.0%)
	VII	2 (4.0%)

**Table 1:** Clino-demographic data of the patients.

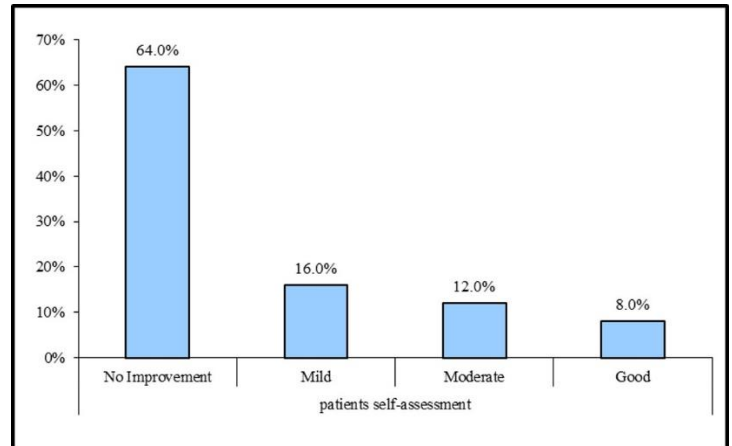
*The photographic assessment after 6 months of treatment was as follow:*

none of our patients showed an excellent response. Most of the patients 36 showed no improvement (72%), mild improvement was in 4 patients (8%), moderate improvement was in 7 patients (14%) and only 3 patients (6%) showed good improvement. Figure (1)



**Figure 1:** The photographic assessment after 6 months of treatment *The patient self-assessment after 6 months of treatment was as follow:*

No improvement was reported in 32 patients (64%), mild improvement in 8 patients (16%), while moderate and good improvement was reported in 6 patients (12%) and 4 patients (8%) respectively. Figure (2)



**Figure 2:** Patient self-assessment after 6 months of treatment *Dermoscopic assessment:*

There was a highly significant statistical decrease in the percentage of vellus hair (v) and an increase in the percentage of terminal hair (T) after treatment than before treatment. There was also a significant statistical decrease in the percentage of hair diameter diversity (HDD) after treatment. while there was no statistically significant difference before and after treatment regarding the presence of peripilar sign (PPS), yellow dot (Y.D.), and black dots (B.D). Table (2)

		Before	After	Test value*	P-value	Sig.
V	Mean $\pm$ SD	30.81 $\pm$ 13.37	29.82 $\pm$ 13.90	3.240*	0.002	HS
	Range	11.5 – 65.2	6.3 – 65.2			
T	Mean $\pm$ SD	69.19 $\pm$ 13.37	70.17 $\pm$ 13.88	-3.185*	0.003	HS
	Range	34.8 – 88.5	34.8 – 93.7			
HDD	Mean $\pm$ SD	36.79 $\pm$ 14.21	34.76 $\pm$ 12.26	2.099*	0.041	S
	Range	20.6 – 80	20 – 77			
SPSU	Mean $\pm$ SD	98.70 $\pm$ 1.21	97.52 $\pm$ 1.76	1.725	0.197	NS
	Range	97.1 – 100	94.8 – 100			
PPS	Negative	30 (60.0%)	33 (66.0%)	0.386*	0.534	NS
	Positive	20 (40.0%)	17 (34.0%)			
Y.D	Negative	18 (36.0%)	22 (44.0%)	0.667*	0.414	NS
	Positive	32 (64.0%)	28 (56.0%)			
B.D	Negative	50 (100.0%)	50 (100.0%)	NA*	NA	NS
	Positive	0 (0.0%)	0 (0.0%)			

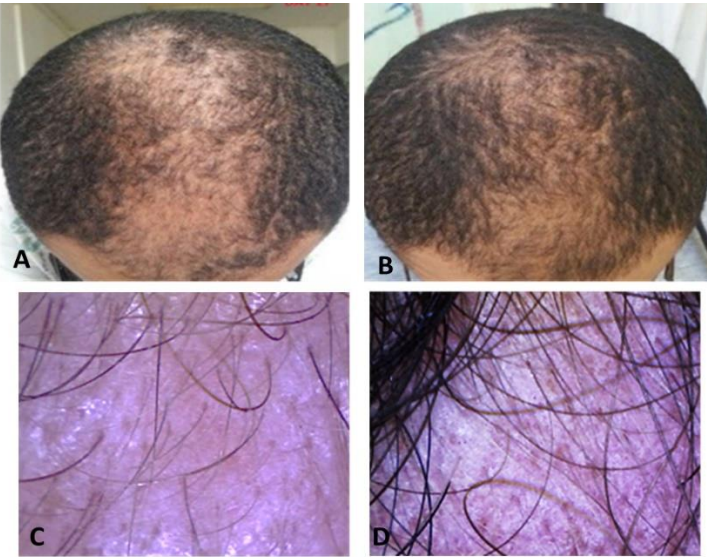
**Table 2:** Comparison between dermoscopic assessment before and after treatment.



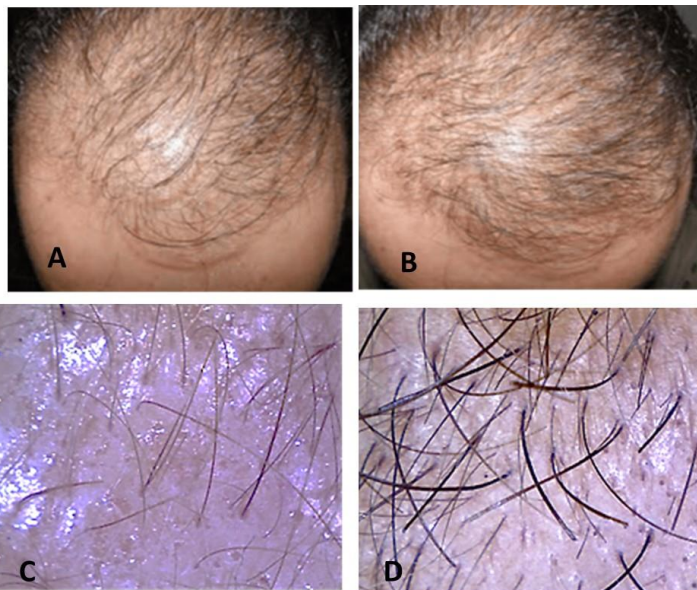
P-value >0.05: Non significant (NS); P-value <0.05: Significant (S); P-value < 0.01: highly significant (HS)

\*: Chi-square test; •: Paired t- test

**Photographic examples of clinical and dermoscopic responses in patients are demonstrated in Figures 3-4.**



**Figure 3:** (A): 27 years old male patient with AGA, grade III. (B): the same patient showed good clinical improvement grade II after topical cetirizine 1% lotion. (C): DermLite® DL4 dermoscopic photos, terminal hair count before treatment was 61.5%. (D): the same patient after treatment terminal hair count became 87.5%



**Figure 4:** (A): 30 years old male patient with AGA, grade V. (B): the same patient showed good clinical improvement grade IV after topical cetirizine 1% lotion. (C): DermLite® DL4 dermoscopic photos, terminal hair count before treatment was 55.6%. (D): the same patient after treatment terminal hair count became 66.7%

There was no statistically significant relation between the clinical response and the age, duration, or grade of AGA.

**Regarding the side effect,** no side effects were observed apart from slight tolerable scalp irritation in 2 patients (2.0%) during the follow-up period and two patients (2.0%) lost follow-up. There were not any systemic side effects reported.

### Discussion:

Androgenetic alopecia is still challenging in both male and female pattern AGA because most treatments either systemic drugs or topical injections have low efficacy and many side effects. [9]

A paper published by **Nieves et al.** was a background to our study. In this paper, they were questioning the role of prostaglandin D2 in hair loss. They showed that prostaglandins play a fundamental role in modulating hair function and the Inhibition of PTGDS might help in male pattern hair loss. [10]

In this study, treatment with topical cetirizine 1% in male patients with AGA stage II, III, IV, V, and VII according to Hamilton-Noorwood classification showed a significant progressive increase in the number of terminal hairs, there was also a significant decrease in the number of vellus hair. There was mild to good photographic improvement.

Our study agreed with **Rossi et al.** preliminary study which showed that using cetirizine, 1% was associated with a marked increase in total hair density, terminal hair density, and a decrease in vellus hair density, [11] but the study lacks the dermoscopic assessment.

**Mostafa et al.** study on topical cetirizine versus topical minoxidil in AGA treatment observed improvement with topical cetirizine but lower than that with minoxidil. [12]

The improvement is not related to the cetirizine anti-H1 effect, but it can be linked to the that cetirizine decreases both inflammation and PGD2 levels which are associated with hair loss and follicular miniaturization.

This agrees with **Charlesworth et al.** trial found that cetirizine led to a decrease in both inflammatory cellular infiltrate and PGD2 production. [13]

Hair growth may be affected by different types of prostaglandins some can stimulate hair growth, and some have a negative impact on the hair. [14]

According to studies on the effect of different prostaglandins on hair follicle cycling, prostaglandins E and F (PGE and PGF $\alpha$ ) have a positive effect, while prostaglandins D increase baldness.<sup>11</sup> PGD2 reduces hair growth, causing miniaturization. From this point, we suggest that using cetirizine, which is anti PGD2, is a promising treatment for AGA.

An interesting study performed by **Garza et al.** assessed changes in gene expression of bald scalp men with AGA. Their results showed prostaglandin D2 synthase (PTGDS) as one of the most highly expressed transcripts in the male balding scalp and there was a significant increase in PGD2 in the balding scalp in comparison

with the haired scalp. This suggests that PGD2 inhibits hair growth. [15]

Also, **Nieves et al.** postulate that PGD2 receptors are in the outer root sheath of the hair follicle. This location of the receptors gives it an important role in follicular activity.<sup>16</sup>

It has been noticed eyelashes and eyebrows growth increased as a side effect of topical use of PG analogues in the treatment of glaucoma, this brought the idea of using it in enhancing hair growth. Latanoprost (PGF2 alpha analogue) is the only food and drug administration approved for eyelashes growth. [14]

In our study, no side effects were observed from part of slight scalp irritation in (2.0%) which agrees with **Mostafa et al.** study which reported no significant side effects with the topical cetirizine solution. [12] This is because the topical route would minimize the possible side effect of systemic antihistaminic.

Finally, the lower number of potential side effects when compared with drugs commonly used in the treatment of AGA, such as minoxidil (dermatitis, headache, and hypotension) can favor the use of topical cetirizine for treatment of AGA in the future.

### Conclusion:

From the present study, topical Cetirizine appears to be safe and may be a promising adjuvant treatment, with minimal side effects, besides, it may be an excellent option for the patients soon as, an economically affordable drug and practical therapeutic option in the treatment of AGA.

The limitation of this study was the lack of a control group. Further studies with a larger number of patients, different concentrations, and longer follow-up periods are required to reach the optimal concentration of topical cetirizine in AGA. Immunohistochemical assessment is required to know more about prostaglandins' role in AGA etiopathogenesis.

**Financial support:** None

**Conflict of Interest:** no conflicts of interest relevant to this study.

### Ethical approval:

Ethical consideration: this study was obtained from the Research ethics committee of the Faculty of Medicine for Girls, Cairo, Al-Azhar University (FMG-IRB) met at the Faculty of Medicine for Girls, Nasr City with IRB 0000001875.

The manuscript is an original unpublished work, and it is not submitted for publication elsewhere.

### References:

1. Matilainen V, Laakso M, Hirso P, et al. Hair loss, insulin resistance, and heredity in middle-aged women. A population-based study. *J Cardiovasc Risk*. 2003;10(3):227-31.
2. Rossi A, Miraglia E, Fortuna M, et al. Topical cetirizine and oral vitamin D: a valid treatment for hypotrichosis caused by

- ectodermal dysplasia. *Journal of the European Academy of Dermatology and Venereology*. 2017;31(2):367-70.
3. Patel B, Velasco MA, Gutierrez FT, et al. Addressing androgenetic Alopecia-A complex disorder-with a multilateral treatment strategy. *MOJ Bioequiv Availab*. 2017;3(1):00025.
4. Garza LA, Liu Y, Yang Z, et al. Prostaglandin D2 inhibits hair growth and is elevated in bald scalp of men with androgenetic alopecia. *Science translational medicine*. 2012;4(126):126ra34-ra34.
5. Yip L, Ruffaut N, Sinclair R. Role of genetics and sex steroid hormones in male androgenetic alopecia and female pattern hair loss: an update of what we now know. *Australas J Dermatol*. 2011;52(2):81-8.
6. English RS Jr. A hypothetical pathogenesis model for androgenic alopecia: clarifying the dihydrotestosterone paradox and rate-limiting recovery factors. *Med Hypotheses*. 2018;111:73-81.
7. Simons FER. Comparative pharmacology of H<sub>1</sub> antihistamines: clinical relevance. *The American journal of medicine*. 2002;113(9):38-46.
8. Hamilton JB. Patterned loss of hair in man; types and incidence. *Ann N Y Acad Sci*. 1951;53[3]:708-28.
9. Huang Y, Zhuo, Li L. Enhancing hair growth in male androgenetic alopecia by a combination of fractional CO<sub>2</sub> laser therapy and hair growth factors. *Lasers Med Sci*. 2017;32(8):1711-1718.
10. Nieves A, Garza LA. Does prostaglandin D2 hold the cure to male pattern baldness? *Exp Dermatol*. 2014;23(4):224-7.
11. Rossi A, Campo D, Fortuna MC, Et al. A preliminary study on topical cetirizine in the therapeutic management of androgenetic alopecia. *J Dermatolog Treat*. 2018;29(2):149-151.
12. Mostafa D, Samadi A, Niknam S, et al. Efficacy of Cetirizine 1% Versus Minoxidil 5% Topical Solution in the Treatment of Male Alopecia: A Randomized, Single-blind Controlled Study. *J Pharm Pharm Sci*. 2021;24:191-199.
13. Charlesworth EN, Kagey-Sobotka A, Norman PS, et al. Effect of cetirizine on mast cell-mediator release and cellular traffic during the cutaneous late-phase reaction. *J Allergy ClinImmunol*. 1989; 83:905–12.
14. X-G. Xu, H-D. Prostanoids and Hair Follicles: Implications for Therapy of Hair Disorders. *Chen Acta Derm Venereol* 2018; 98: 318–323.
15. Garza LA, Liu Y, Yang Z, et al. Prostaglandin D2 inhibits hair growth and is elevated in bald scalp of men with androgenetic alopecia. *Sci Transl Med*. 2012;21;4(126):126ra34.
16. Nieves A, Garza LA. Does prostaglandin D2 hold the cure to male pattern baldness? *Exp Dermatol*. 2014;23(4):224-7.